

Content available at: <https://www.ipinnovative.com/open-access-journals>

IP International Journal of Comprehensive and Advanced Pharmacology

Journal homepage: <https://www.ijcap.in/>

## Original Research Article

# Sophora interrupta bedd., ameliorates doxorubicin induced myocardial necrosis by attenuation of oxidative stress and structural cardiomyocyte alterations in rats

Jyothi Basini<sup>1\*</sup>, Vandana Mallavarapu<sup>1</sup><sup>1</sup>Dept. of Pharmacology, Seven Hills College of Pharmacy (Autonomous), Venkataramapuram, Tirupati, Andhra Pradesh, India

## ARTICLE INFO

## Article history:

Received 18-11-2023

Accepted 06-12-2023

Available online 26-12-2023

## Keywords:

Cardioprotective activity

Sophora interrupta Bedd

Doxorubicin

## ABSTRACT

**Aim:** The present study aimed at investigating the cardioprotective activity of *Sophora interrupta* Bedd against doxorubicin induced myocardial necrosis by attenuation of oxidative stress and structural cardiomyocyte alterations in rats.

**Materials and Methods:** The experimental procedure was carried out with male Wistar rats inducing cardiotoxicity by administering Doxorubicin in normal saline 3.750 mg/kg i.p on day 7<sup>th</sup>, 14<sup>th</sup>, 21<sup>st</sup> and 28<sup>th</sup> and treated with test extract of *Sophora interrupta* Bedd at a dose of 200 & 400 mg/kg, b.wt., per orally once daily for 28 days. The heart weight to body weight ratio was measured to evaluate the effect of extract on MI. The plasma was evaluated for the biochemical parameters and cardiac markers. Pro-oxidant & anti-oxidant levels were measured along with the histopathological examination of the heart.

**Results:** The test extracts *Sophora interrupta* Bedd showed a significant ( $p < 0.001$ ) restoration of the altered plasma biochemical parameters and cardiac markers reducing the extent of damage in heart musculature. The anti-oxidant effect of the test extract plays a prominent role in curative effect of cardiomyopathy associated with doxorubicin.

**Conclusion:** The test extract of *Sophora interrupta* Bedd was beneficial for doxorubicin induced cardiotoxicity by ameliorating oxidative stress and restoring the abnormal structural changes in the heart tissue.

This is an Open Access (OA) journal, and articles are distributed under the terms of the [Creative Commons Attribution-NonCommercial-ShareAlike 4.0 License](https://creativecommons.org/licenses/by-nc-sa/4.0/), which allows others to remix, tweak, and build upon the work non-commercially, as long as appropriate credit is given and the new creations are licensed under the identical terms.

For reprints contact: [reprint@ipinnovative.com](mailto:reprint@ipinnovative.com)

## 1. Introduction

Despite of advances in the field of cardiovascular health promotion contributed by scientific research over the past several decades, cardiovascular disease (CVD) remains to be the leading cause of premature deaths across the globe.<sup>1</sup> Of the entire death takes place due to CVD, 80% of the deaths are from low-middle income countries. It has been projected that by the year 2030, >23.3 million people will die annually from CVDs.<sup>2</sup> Myocardial Infarction (MI) is necrosis in the heart muscle due to the lack of the oxygen required by the myocardium that cannot be supplied by the coronary blood vessels. It is characterized by chest

pain or discomfort that may travel into the shoulder, arm, back, neck or jaw. Approximately 90% of myocardial infarction results from an acute thrombus that obstructs an atherosclerotic coronary artery. The highest risk of fatality occurs within the initial hours of onset of AMI. Thus, early diagnosis of cardiac ischemia is critical for the effective management of patients with AMI. Some disease factors contribute to the risk of myocardial infarction and they include diabetes mellitus (type 1 or 2), high blood pressure, dyslipidemia/hypercholesterolemia and particularly high amount of low-density lipoprotein, low amount of high density lipoprotein, high triglycerides, and obesity.<sup>3</sup> When the prevalence of cardiovascular disease were not explained completely on the basis of modifiable and non-modifiable

\* Corresponding author.

E-mail address: [jyothiphdcologyvmk@gmail.com](mailto:jyothiphdcologyvmk@gmail.com) (J. Basini).

ones, the search of additional markers and risks were enlisted which might answer and unveil the relationship and could be of great help in risk stratification and improving treatment.

*Sophora interrupta* Bedd is a woody perennial shrub which belongs to the family fabaceae. *Sophora interrupta* Bedd is a woody perennial shrub which grows endemically in seshachalam hill ranges in Tirumala, India. More than 150 species in this genus have a long history of use in traditional Chinese medicine. Several phytochemical researches, *in vivo* and *in vitro* experiments and clinical practices have demonstrated that *Sophora* contains many phytoconstituents like matrine, oxymatrine type of alkaloids, flavonoids, saponins and polysaccharides which possess wide reaching pharmacological actions, including anti-oxidant, anti-cancer, anti asthmatic, antimicrobial, anti-viral, antidote, anti-pyretic, cardiogenic, anti-inflammatory, diuretic and in the treatment of skin diseases like eczema, colitis and psoriasis.<sup>4</sup>

## 2. Materials and Materials

Doxorubicin was procured from the Naprod life sciences Ltd, all the reagents & kits used for the analysis are of analytical grade and purchased from Span diagnostics Ltd. The plant material of *Sophora interrupta* Bedd was collected and authenticated. The dried leaves of *Sophora interrupta* Bedd were pulverised into a coarse powder. The coarse powder was then subjected to continuous hot percolation in soxhlet apparatus with hydro alcohol as solvent and extracted till the solvent becomes colourless. The extract was evaporated under reduced pressure using rotary evaporator at a low temperature of 40°C until the extract turns syrupy and then the syrupy extract was transferred to an evaporating dish for drying at room temperature.

### 2.1. Experimental procedure

The experiment was carried out with male Wistar rats weighing 180-220g. They were housed in polypropylene cages (47X34X20cm) lined with husk, under a 12-hour light / dark cycle at around 22°C with 50% humidity. The rats had free access to water and fed on a standard pellet diet. A total of 24 rats were randomly divided into 4 groups of six rats each; Group 1 with healthy rats or Vehicle control received 0.9 % NaCl solution in a single oral dose of 2ml/kg/day throughout the experimental period; Group 2, healthy rats received Doxorubicin in normal saline (3.750 mg/kg) i.p on day 7, 14, 21 and 28 to reach a total cumulative dose of (15 mg/kg) (n=6), [20]; Group 3, rats received test extract of *Sophora* at a dose of 200 mg/kg, b.wt., per orally once daily throughout the experimental period; Group 4, rats received test extract of *Sophora* at a dose of 400 mg/kg, b.wt., per orally once daily throughout the experimental period.

One week after the last i.p injection of doxorubicin, the animals were euthanized by decapitation method under mild anaesthesia. 2 ml of blood samples will be collected by retro-orbital plexus and centrifuged at 4°C at 4000 rpm for 15 minutes to separate the plasma. The plasma was used for the estimation of biochemical parameters such as Alanine aminotransferase (ALT), Aspartate aminotransferase (AST), Alkaline Phosphatase, Lactate dehydrogenase (LDH) and Cardiac Markers such as CK-MB and Creatine kinase (CK).<sup>5</sup>

All rats were anesthetized with intraperitoneal injection of pentobarbital sodium (40 mg/kg body). Then, the hearts were immediately removed and weighed. The heart weight to body weight ratio was measured to evaluate the effect of extract on MI. 100 mg of heart tissue was homogenized in 10 volumes of 100mM KH<sub>2</sub>PO<sub>4</sub> buffer containing 1mM EDTA, pH 7.4 and centrifuged at 12,000×g for 30 min at 4°C. The supernatant was collected and used for estimation of tissue parameters such as Superoxide Dismutase (SOD), Catalase (CAT), Malondialdehyde (MDA), and Glutathione Peroxidase (GPx).<sup>6</sup>

### 2.2. Histopathological examination

Animals were sacrificed on the defined days, and immediately their hearts were completely and intactly expelled, washed with saline and instantly fixed in 10% buffered formalin. The hearts were stored in formalin overnight and then every globe was horizontally sectioned at about 2-3 mm thickness by the Automatic Tissue Processor. All the sections were embedded in paraffin blocks separately, sections cut at 5 μm by Leica 2BS Microtome and stained with hematoxylin and eosin (H&E). These sections were then examined under Light Microscope using 10 X & 40 X magnifications. The histopathologic study was blinded to the treatment assignment of various study groups.

### 2.3. Statistical analysis

All the data were expressed as Mean ± Standard error mean (SEM). The difference between groups analysis was performed with one-way ANOVA followed by Dunnett's test using Graph Pad Prism Software.

## 3. Results

### 3.1. Effect of *Sophora* extract on Body weight and heart weight in DOX induced myocardial necrosis in rats

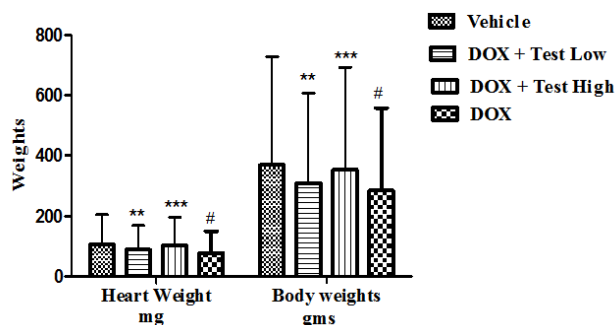
In DOX-treated group, there was significant decrease in body weight and heart weight as compared to that of normal rats. In groups pre-treated with 200 mg/kg of test extract of *Sophora*, increase in body weight and heart weights were observed statistically significant and highly significant with high dose i.e., 400 mg/kg of test extract when compared

**Table 1:** Effect of Sophora extract on Body weight and heart weight in DOX induced myocardial necrosis in rats

Parameter	Vehicle	DOX	DOX + Test Low	DOX + Test High
Heart Weight (gms)	205.6 ± 8.69	149.4 ± 7.43 <sup>#</sup>	169.7 ± 8.64 <sup>**</sup>	196.6 ± 7.50 <sup>***</sup>
Body weights (mg)	727.4 ± 12.34	558.4 ± 10.42 <sup>#</sup>	606.8 ± 13.32 <sup>**</sup>	693.4 ± 14.82 <sup>***</sup>

with DOX treated rats (\$ and Figure 1).

Data was expressed as Mean ± SEM. DOX group was compared to vehicle control group <sup>#</sup>p < 0.001. Treatment group was compared with diabetic control \*p < 0.05; \*\*p < 0.01; \*\*\*p < 0.001 using one-way ANOVA with Dunnett’s test. Table 1



**Figure 1:** Effect of Sophora extract on Body weight and heart weight in DOX induced myocardial necrosis in rats

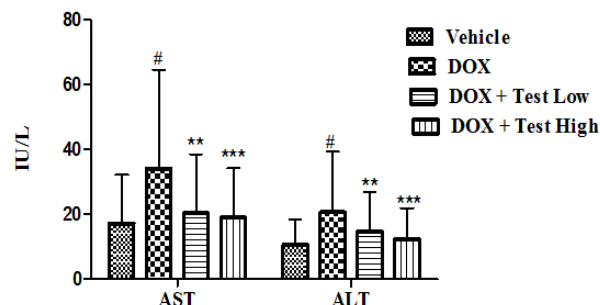
Data was expressed as Mean ± SEM. DOX group was compared to vehicle control group <sup>#</sup>p < 0.001. Treatment group was compared with diabetic control \*p < 0.05; \*\*p < 0.01; \*\*\*p < 0.001 using one-way ANOVA with Dunnett’s test. Figure 1

### 3.2. Effect of Sophora extract on cardiac injury markers in DOX induced myocardial necrosis in rats

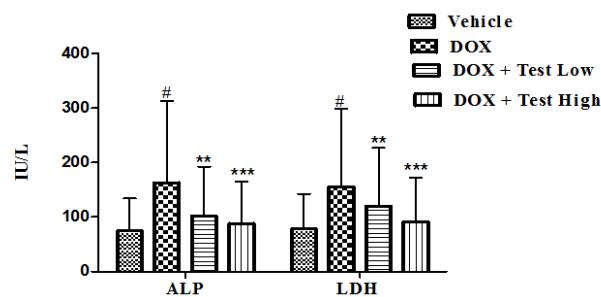
The activities of plasma AST, ALT, ALP, LDH, CK and CK-MB of Vehicle treated and DOX induced myocardial infarction rats were given in Table 1. Increased activities of AST, ALT, ALP, LDH, CK and CKMB were observed in the DOX-induced rats. Treatment with Sophora extract at doses 200 and 400 mg/kg body weight ameliorated the above parameters significantly (Table 2 and Figures 2, 3 and 4).

Data was expressed as Mean ± SEM. DOX group was compared to vehicle control group <sup>#</sup>p < 0.001. Treatment group was compared with diabetic control \*p < 0.05; \*\*p < 0.01; \*\*\*p < 0.001 using one-way ANOVA with Dunnett’s test. Table 2

Data was expressed as Mean ± SEM. DOX group was compared to vehicle control group <sup>#</sup>p < 0.001. Treatment group was compared with diabetic control \*p < 0.05; \*\*p < 0.01; \*\*\*p < 0.001 using one-way ANOVA with Dunnett’s test. Figure 2

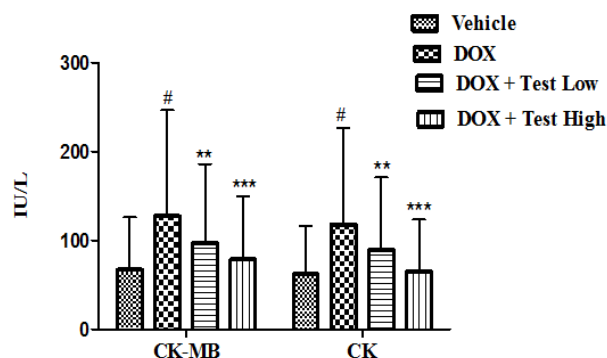


**Figure 2:** Effects of Sophora extract on AST and ALT levels in DOX induced myocardial necrosis in rats



**Figure 3:** Effects of Sophora extract on AST and ALT levels in DOX induced myocardial necrosis in rats

Data was expressed as Mean ± SEM. DOX group was compared to vehicle control group <sup>#</sup>p < 0.001. Treatment group was compared with diabetic control \*p < 0.05; \*\*p < 0.01; \*\*\*p < 0.001 using one-way ANOVA with Dunnett’s test. Figure 3



**Figure 4:** Effects of Sophora extract on AST and ALT levels in DOX induced myocardial necrosis in rats

**Table 2:** Effects of Sophora extract on AST and ALT levels in DOX induced myocardial necrosis in rats

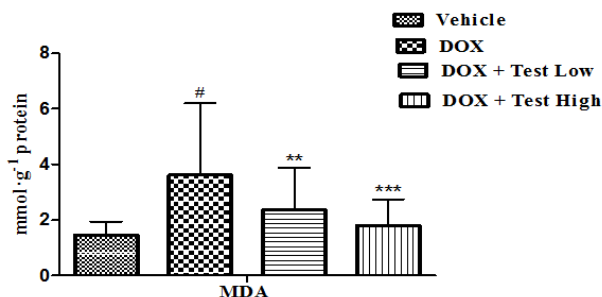
Parameter	Vehicle	DOX	DOX + Test Low	DOX + Test High
AST (IU/L)	32.1 ± 2.21	64.5 ± 3.58 <sup>#</sup>	48.5 ± 2.33 <sup>**</sup>	34.2 ± 3.80 <sup>***</sup>
ALT (IU/L)	18.4 ± 2.71	39.2 ± 2.08 <sup>#</sup>	26.8 ± 2.73 <sup>**</sup>	21.9 ± 2.81 <sup>***</sup>
ALP (IU/L)	134.2 ± 14.98	312.8 ± 13.25 <sup>#</sup>	192.6 ± 12.03 <sup>**</sup>	165.6 ± 11.32 <sup>***</sup>
LDH (IU/L)	142.5 ± 13.94	298.4 ± 12.74 <sup>#</sup>	227.14 ± 13.49 <sup>**</sup>	172.1 ± 11.49 <sup>***</sup>
CK-MB (IU/L)	126.2 ± 7.84	246.5 ± 8.09 <sup>#</sup>	186.2 ± 8.39 <sup>**</sup>	149.7 ± 7.76 <sup>***</sup>
CK (IU/L)	116.2 ± 8.58	226.5 ± 9.69 <sup>#</sup>	171.4 ± 7.69 <sup>**</sup>	123.70 ± 6.86 <sup>***</sup>

Data was expressed as Mean ± SEM. DOX group was compared to vehicle control group <sup>#</sup>p < 0.001. Treatment group was compared with diabetic control \*p < 0.05; \*\*p < 0.01; \*\*\*p < 0.001 using one-way ANOVA with Dunnett’s test. Figure 4

**3.3. Effect of Sophora extract on Tissue parameters in DOX induced myocardial necrosis in rats**

DOX induction significantly increased level of MDA as a marker of lipid peroxidation and decreased levels of SOD, Catalase and GPx in heart tissue in as compared to vehicle. Treatment with Sophora extract (200 and 400 mg/kg, b.wt.) restored the levels of altered MDA, SOD, Catalase and GPx in heart tissue when compared with DOX alone treated rats (Table 3 and Figures 5, 6 and 7).

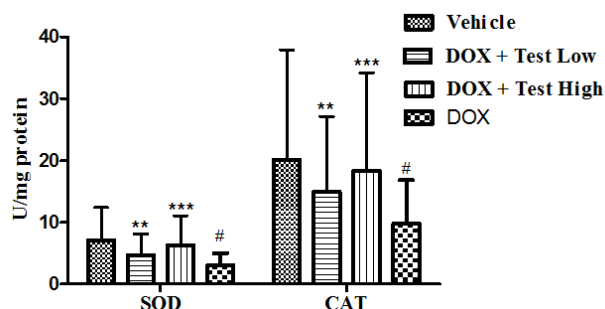
Data was expressed as Mean ± SEM. DOX group was compared to vehicle control group <sup>#</sup>p < 0.001. Treatment group was compared with diabetic control \*p < 0.05; \*\*p < 0.01; \*\*\*p < 0.001 using one-way ANOVA with Dunnett’s test. Figure 4



**Figure 5:** Effect of Sophora extract on tissue MDA levels in DOX induced myocardial necrosis in rats

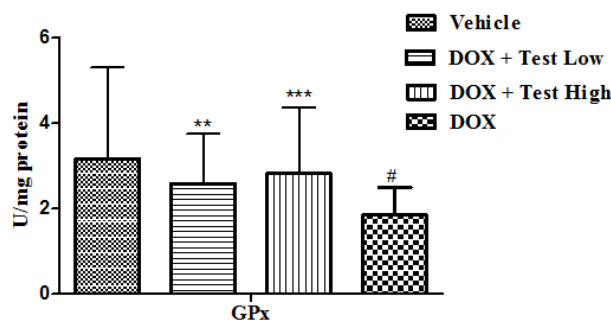
Data was expressed as Mean ± SEM. DOX group was compared to vehicle control group <sup>#</sup>p < 0.001. Treatment group was compared with diabetic control \*p < 0.05; \*\*p < 0.01; \*\*\*p < 0.001 using one-way ANOVA with Dunnett’s test. Figure 5

Data was expressed as Mean ± SEM. DOX group was compared to vehicle control group <sup>#</sup>p < 0.001. Treatment group was compared with diabetic control \*p < 0.05; \*\*p < 0.01; \*\*\*p < 0.001 using one-way ANOVA with Dunnett’s



**Figure 6:** Effect of Sophora extract on tissue SOD & CAT levels in DOX induced myocardial necrosis in rats

test. Figure 6



**Figure 7:** Effect of Sophora extract on tissue SOD & CAT levels in DOX induced myocardial necrosis in rats

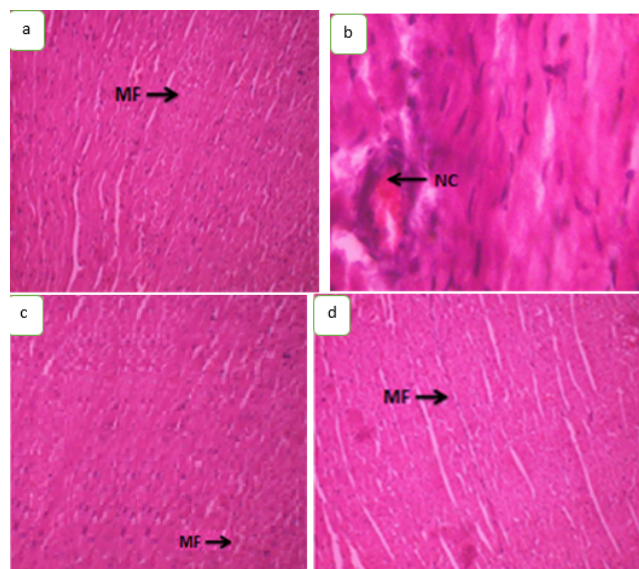
Data was expressed as Mean ± SEM. DOX group was compared to vehicle control group <sup>#</sup>p < 0.001. Treatment group was compared with diabetic control \*p < 0.05; \*\*p < 0.01; \*\*\*p < 0.001 using one-way ANOVA with Dunnett’s test. Figure 7

**4. Discussion**

Acute myocardial necrosis, or myocardial infarction (MI), is brought on by an imbalance between the coronary blood supply and the myocardial demand. Lipid peroxidation, hyperlipidaemia, free radical damage, and hyperglycaemia are some of the biochemical changes that follow MI, which cause both qualitative and quantitative changes to the myocardium. Restoring the blood flow to the ischemic

**Table 3:** Effect of Sophora extract on Tissue parameters in DOX induced myocardial necrosis in rats

Parameter	Vehicle	DOX	DOX + Test Low	DOX + Test High
MDA (mmol·g <sup>-1</sup> protein)	1.94 ± 0.98	6.21 ± 1.02 <sup>#</sup>	3.88 ± 0.87 <sup>**</sup>	2.74 ± 0.87 <sup>***</sup>
SOD activity (U/mg protein)	12.43 ± 1.76	5.01 ± 1.09 <sup>#</sup>	8.11 ± 1.24 <sup>**</sup>	11.08 ± 1.62 <sup>***</sup>
Catalase (U/mg of protein)	37.90 ± 2.32	16.86 ± 2.73 <sup>#</sup>	27.15 ± 2.67 <sup>**</sup>	34.21 ± 2.49 <sup>***</sup>
GPx activity (U/mg of protein)	5.31 ± 1.03	2.49 ± 1.22 <sup>#</sup>	3.75 ± 1.43 <sup>**</sup>	4.37 ± 1.28 <sup>***</sup>



**Figure 8:** Histopathological examination; **a:** Vehicle Control showing normal myocardial architecture & Regular cell distribution MF: Myocardial fibers; **b:** DOX control showing myocardial necrosis, collapsed myocardial fibres NC: Necrosis; **c:** DOX + Test low dose (200 mg/kg) control showing Mild infiltration of lymphocytes; **d:** DOX + Test high dose (400 mg/kg) control showing histoarchitecture near to normal rats with no evidence of focal necrosis

tissue and minimizing the damage done at the scene are two aspects of treating ischemia injury. During cardiac ischemia, the production of hydroxyl radicals (OH) and superoxide anion (O<sub>2</sub><sup>-</sup>) increases reactive oxygen species, which damages the antioxidant defense system, breaks down cell membranes, and produces lipid peroxides.

The purpose of the current study was to employ doxorubicin to cause cardiotoxicity and oxidative stress, which includes hydroxyl radical-induced myocardial necrosis. When doxorubicin is broken down, it forms the deadly, short-lived semiquinone form, which reacts with molecular oxygen to start a chain reaction that produces reactive oxygen species (ROS). The other way that doxorubicin causes stress is by the creation of a free radical complex called anthracycline iron (Fe<sup>2+</sup>). The latter creates the (OH.) radical when it combines with hydrogen peroxide. Myocardial necrosis results from ROS's reaction with lipids, proteins, and other biological components, which damages the heart muscle cells' mitochondria and

cell membranes.<sup>7</sup>

As doxorubicin was administered, the animals' body weight and heart weight significantly decreased as compared to the vehicle control group, which suggested myofibril loss and cardiac necrosis.<sup>8</sup> In experimental animals, the effects of repeated, prolonged DOX administration on body weight reduction, debilitation, and death are thought to be multifactorial. In comparison to rats treated with DOX, pretreatment with test extract of Sophoria at both dose levels (200 mg/kg and 400 mg/kg) increased weights of the animals and heart tissue and lessened myocardial necrosis.

The mechanism of DOX-induced cardiotoxicity is linked to a reduction in endogenous antioxidants and an increase in oxygen free radicals, which raises oxidative stress and causes subcellular alterations in the heart. When compared to animals treated with a vehicle, the levels of AST, ALT, and ALP in the DOX treated groups shown a substantial rise, indicating myocardial damage. Myocardial infarction or liver damage have been linked to mild increases in AST. The extent of myocardial damage increases with AST and ALP activity.<sup>8</sup> The findings suggest that DOX may harm the liver and heart when used over an extended length of time. When comparing pre-treatment groups to DOX-treated groups, there was a substantial drop in AST, ALT, and ALP levels. The current findings imply that administration of Sophora test extract is in charge of preserving the cardiac muscle's normal architectural integrity, which may prevent myocardial damage and the release of cardiac injury markers.

When diagnosing cardiac injury, the cardiac biomarker enzymes CK, CK-MB, and LDH were taken into consideration as markers. Elevations of CK, CK-MB, and LDH indicate a significant increase in cardiotoxicity caused by doxorubicin. In animals induced by DOX, treatment with test extract at both dose levels (200 mg/kg & 400 mg/kg) dramatically reduced the increased levels of CK, CK-MB, and LDH. The amount of damage to the heart's musculature is reflected in the plasma's levels of CK, CK-MB, and LDH activities.<sup>7</sup>

Due to DOX's strong affinity for phospholipids, it accumulates in heart tissue, which makes it more vulnerable to oxidative stress-related damage because heart tissue has low levels of antioxidant enzymes.<sup>9</sup> Doxorubicin-associated cardiomyopathy in heart failure is correlated with elevated oxidative stress. Following doxorubicin induction, there was a notable rise in MDA and a decrease in GPx, CAT, and SOD

when compared to animals treated with a vehicle, indicating oxidative stress on the heart tissue. The free radicals that DOX produced with the biomembrane and the ensuing lipid peroxidation are what caused the observed increased MDA levels and decrease in antioxidant enzymes. Pretreatment with a Sophora test extract raised the antioxidant enzymes preventing oxidative stress in the heart tissue and decreased the elevated MDA levels. Numerous antioxidants, including flavonoids and polyphenols, have been employed in the past to combat DOX-induced cardiotoxicity, according to reports.<sup>10</sup>

In cardiac tissues intoxicated with DOX, histopathology revealed myocardial atrophy, nuclear condensation of chromosomes, and cytoplasmic vacuoles. Significant fatty blockage in the blood vessel and foamy-looking cytoplasm were cleared after DOX treatment, along with nuclear deterioration. All of these morphological deteriorations brought on by DOX were significantly improved after using Sophora test extract. Test extract of Sophora at doses of 200 mg/kg and 400 mg/kg showed significant protection against structural alterations in the cardiomyocytes of animals intoxicated with DOX. Sophora may have a protective effect on cardiomyocytes because of its antioxidant potential, which increases tissue antioxidant status and inhibits the generation of free radicals mediated by oxidative stress.

## 5. Conclusion

Among cancer survivors, cardiovascular disease (CVD) is the second most common cause of long-term morbidity and mortality. The use of targeted therapies and conventional chemotherapy is linked to a higher risk of myocardial dysfunction, irreversible heart failure, and even death. Plants with phenolic and flavonoid content have been shown by researchers to have a wide range of biological properties, such as cardio-protection, anti-fibrosis, and anticancer effects. Numerous medicinal plants with antioxidant activity have been successful in preventing the cardiotoxicity linked to DOX induction. Therefore, it makes sense to investigate additional naturally occurring plant-derived compounds that prevent DOX from being cardiotoxic. In groups 2, 3, and 4, the current study employed doxorubicin to cause cardiotoxicity. According to histopathological observations of heart tissue, the test extract of Sophora may be protective against DOX-induced cardiotoxicity by reducing oxidative stress. Nevertheless, additional validation of this fundamental research in a more clinically relevant model is required to fully understand the mechanism and create preventative measures against DOX-induced cardiotoxicity.

## 6. Source of Funding

This research received no financial support from any funding agency.

## 7. Conflicts of Interest

The authors declare no conflicts of interest to disclose.


## 8. Acknowledgement

Authors are thankful to the management of Sri Padmavathi Medical College for Women Hospital, SVIMS, Tirupati, and Seven Hills College of Pharmacy, Tirupati for their continuous support for successful completion of this study.

## References

- Vos T, Lim SS, Abbafati C. Global burden of 369 diseases and injuries in 204 countries and territories, 1990-2019: a systematic analysis for the Global Burden of Disease Study 2019. *Lancet*. 2019;396(10258):1204–22.
- Roth GA, Mensah GA, Johnson C, Addolorato G, Ammirati E, Baddour LM, et al. Global Burden of Cardiovascular Diseases and Risk Factors, 1990-2019: Update From the GBD 2019 Study. *J Am Coll Cardiol*. 2020;76(25):2982–3021.
- Mechanic OJ, Gavin M, Grossman SA. Acute Myocardial Infarction. StatPearls [Internet]. Treasure Island (FL): StatPearls Publishing; 2023. [Updated 2023 September 3]. Available from: <https://www.ncbi.nlm.nih.gov/books/NBK459269/>.
- Mathi P, Bokka VR, Botlagunta M. Medicinal uses and biological activities of Sophora Interrupta bed-A review. *Int J Pharm*. 2015;5(1):265–73.
- Ferrannini G, Rosenthal N, Hansen MK, 4 EF. Liver function markers predict cardiovascular and renal outcomes in the CANVAS Program. *Cardiovasc Diabeto*. 2022;21(1):127. doi:10.1186/s12933-022-01558-w.
- Weydert CJ, Cullen JJ. Measurement of superoxide dismutase, catalase and glutathione peroxidase in cultured cells and tissue. *Nat Protoc*. 2010;5(1):51–66.
- Rawat P, Jaiswal A, Khurana A, Bhatti JS, Navik U. Doxorubicin-induced cardiotoxicity: An update on the molecular mechanism and novel therapeutic strategies for effective management. *Biomed Pharmacother*. 2021;139:111708. doi:10.1016/j.biopha.2021.111708.
- Swamy AV, Gulliaya S, Thippeswamy A, Koti BC, Manjula DV. Cardioprotective effect of curcumin against doxorubicin-induced myocardial toxicity in albino rats. *Indian J Pharmacol*. 2012;44(1):73–7.
- Cappetta D, De Angelis A, Sapio L, Prezioso L, Illiano M, Quaini F, et al. Oxidative Stress and Cellular Response to Doxorubicin: A Common Factor in the Complex Milieu of Anthracycline Cardiotoxicity. *Oxid Med Cell Longev*. 2017;p. 1521020. doi:10.1155/2017/1521020.
- Sirangelo I, Liccardo M, Iannuzzi C. Hydroxytyrosol Prevents Doxorubicin-Induced Oxidative Stress and Apoptosis in Cardiomyocytes. *Antioxidants (Basel)*. 2022;11(6):1087. doi:10.3390/antiox11061087.

## Author biography

**Jyothi Basini**, Professor  <https://orcid.org/0000-0003-1276-0376>

**Vandana Mallavarapu**, Post Graduate Student

**Cite this article:** Basini J, Mallavarapu V. Sophora interrupta bedd., ameliorates doxorubicin induced myocardial necrosis by attenuation of oxidative stress and structural cardiomyocyte alterations in rats. *IP Int J Comprehensive Adv Pharmacol* 2023;8(4):250-255.