

Content available at: <https://www.ipinnovative.com/open-access-journals>IP International Journal of Comprehensive and Advanced
PharmacologyJournal homepage: <https://www.ijcap.in/>

Case Report

Review on optic atrophy

**Kameshwaran¹, S Shameem¹, A Saranya^{1,*}, KP Sathish¹, K Shanmugapriya¹,
SM Shabariraj¹**¹Dept. of Pharmacology, SSM College of Pharmacy, Jambai, Pudur, Tamil Nadu, India

ARTICLE INFO

Article history:

Received 23-09-2023

Accepted 18-10-2023

Available online 02-11-2023

Keywords:

Optic atrophy

Ischemic optic neuropath

Nerve disease

ABSTRACT

The illness known as optic atrophy damages the eye. It causes anterior ischemic optic neuropathy, also known as glaucoma, and strokes of the optic nerve. A change in vision, notably blurred vision, problems with peripheral (side) vision, problems with colour vision, and a loss of vision sharpness, are indications of optic atrophy. The final stage of a disease process that affects the retinogeniculate section of the visual pathway is called optic atrophy, and it is identified by the non-specific symptom of optic disc pallor. As a result, rather than acting like a real peripheral nerve, the optic nerve, with its 1.2 million fibres, functions more like a white matter tract. Pial capillaries that supply the optic nerve head experience degeneration, which contributes to the pallor of the optic disc seen in optic atrophy.

This is an Open Access (OA) journal, and articles are distributed under the terms of the [Creative Commons Attribution-NonCommercial-ShareAlike 4.0 License](#), which allows others to remix, tweak, and build upon the work non-commercially, as long as appropriate credit is given and the new creations are licensed under the identical terms.

For reprints contact: reprint@ipinnovative.com

1. Introduction

The pathological term "optic atrophy" describes the shrinkage of the optic nerve brought on by the axonal degeneration of retinal ganglion cells (RGCs). Given that atrophy implies disuse, the term "optic atrophy" is considered misleading. Therefore, "optic neuropathy" would be a more appropriate word for optic atrophy. However, that phrase is also debatable because optic neuropathy may not manifest in some conditions, such as primary optic atrophy or traumatic brain injury.¹

The final stage of a disease process that affects the retinogeniculate section of the visual pathway is called optic atrophy, and it is identified by the non-specific symptom of optic disc pallor. The central nervous system is typically not capable of these activities, whereas the peripheral nervous system has an inherent capacity for repair and regeneration. Oligodendrocytes and reactive astrocytes, which express a number of inhibitory factors for axonal regeneration,

heavily myelinate the optic nerve's axons.²

As a result, rather than acting like a real peripheral nerve, the optic nerve, with its 1.2 million fibres, functions more like a white matter tract. Pial capillaries that supply the optic nerve head experience degeneration, which contributes to the pallor of the optic disc seen in optic atrophy. The foundation for the onset of ocular atrophy is this neurovascular degeneration.³

1.1. Synonym

Leber's hereditary optic neuropathy

1.2. Causes and symptoms

Nerve fibres that carry impulses to the brain make up the optic nerve. Something is interfering with the optic nerve's ability to convey these impulses in the case of optic atrophy. There are many potential causes of the interference, including glaucoma, anterior ischemic optic neuropathy, also known as an optic nerve stroke. A change in vision is

* Corresponding author.

E-mail address: saranyaannamalai999@gmail.com (A. Saranya).

one of the signs of optic atrophy, specifically hazy vision that is hazy.peripheral (side) vision problems problems with colour perception. a decline in eye clarity.⁴

2. Case Report

We discuss a 35-year-old woman’s case. Her main symptoms included double vision, visual field distortion, and a need for an ophthalmological check.

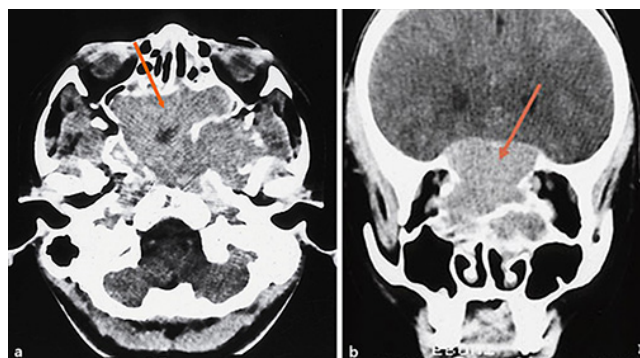


Fig. 1: Horizontal (a) and frontal (b) Orbital findings on a female patient who was 13 years old. The condition of the intracranial optic nerves was not known at the time, although CT scan images at that time showed a sizable tumour extending from the sphenoid sinus to the ethmoid sinus. b The optic nerve may be indicated by the orbits and chiasmal region (arrow).

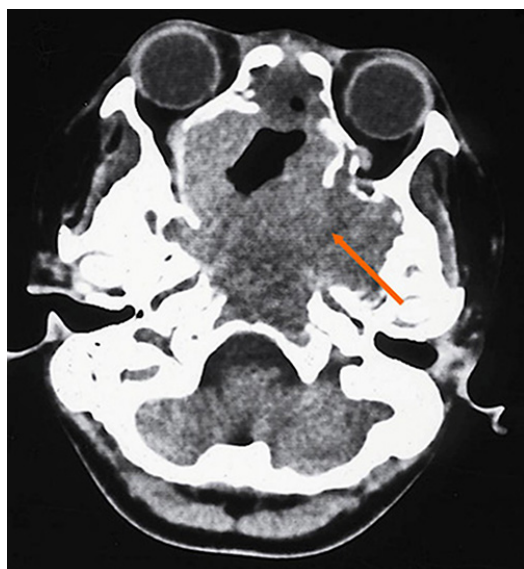


Fig. 2: The majority of the tumour had been eliminated in the CT scan taken after the initial surgery and radiation treatment, although some was still visible within the sphenoid sinus.

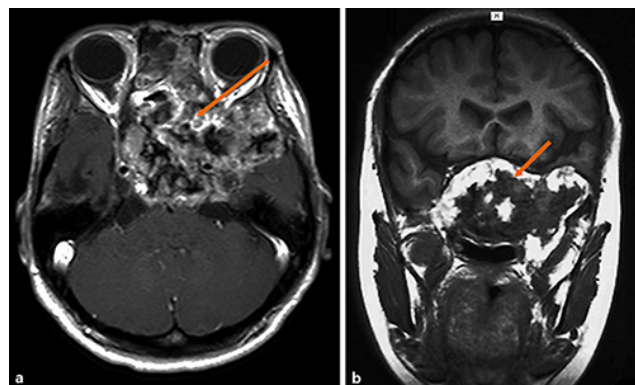


Fig. 3: Horizontal (a) and frontal (b) oblique T1-weighted MRI images of the patient at age 23. The sphenoid sinus exhibits vestiges of a large cell tumour, according to the MRI.

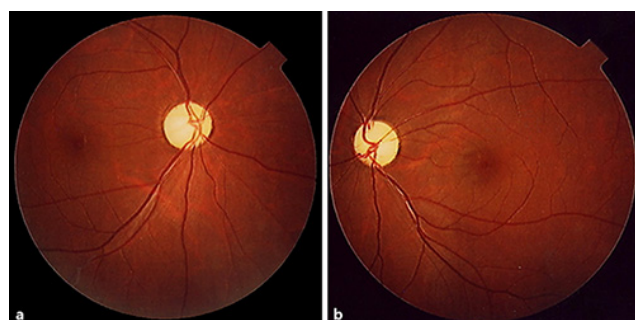

Fig. 4: Right and left fundus images of the patient at age 24 are shown in the images below. Fundus images showed significant optic atrophy in both eyes.

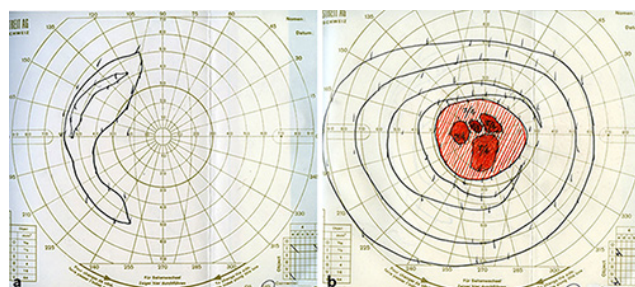


Fig. 5: Right eye (a) and left eye (b) visual field perimetry results. Only the nasal side of the right eye’s peripheral vision remained arced. Relative scotomas were seen within a 20-degree radius of the absolute scotomas in four spots in the centre of the left eye.

2.1. Medical history

The patient observed a loss in visual acuity in both eyes as well as visual field abnormalities after receiving a large cell tumour diagnosis at age 13. She had corrected visual acuities of 0.1 in the right eye and 0.5 in the left eye at that age. The condition of the intracranial optic nerves was unknown at the time, and a CT scan at that time showed a sizable tumour extending from the sphenoid sinus to the ethmoid sinus (Figure 1a,b). At the Kyoto Prefectural Medical College of Otolaryngology, the tumour was removed when the patient was 14 years old. A month later, the tumour was partially resected, and radiation therapy (3,168 rad) was administered at the same hospital's neurosurgery division. A sphenoid invasion resection was additionally carried out three months later.⁵

We were asked to conduct an ophthalmological check on the patient when she was 24 years old. She had a left eye visual acuity of 0.2 (0.3 S - 0.75 = C - 1.25 A 90°) and a right eye visual acuity of 0.02 (0.03 S - 1.50 = C - 2.00 A 110°). Her right and left eyes' intraocular pressures were 11 and 13 mm Hg, respectively. Esotropia, measured as 30 prism dpt at near vision and 35 prism dpt at distant vision, was present with regard to eye position. She has a minor abduction failing in her left eye. In addition, ocular protrusion of 8 millimetres in her right eye and 8.5 millimetres in her left eye (base 98 millimetres) was seen. The anterior ocular segment and ocular surface were normal.⁵

2.2. Diagnosis

The optic disc, where the optic nerve enters the back of the eye, will be examined by the physician. The optic disc will turn pale in cases of optic atrophy due to a shift in blood vessel flow. The ophthalmologist may also administer further examinations to evaluate your central, peripheral, and colour vision.⁶

2.3. Treatment

To reverse optic atrophy, there is no proven treatment. The best defence at the moment is early detection. If specific treatment for the underlying problem begins before optic atrophy develops. The vision may still be beneficial. For instance, in cases of compressive and toxic neuropathies, timely identification and treatment are beneficial.^{7,8}

3. Conclusion

The final stage of a disease process that affects the retinogeniculate section of the visual pathway is called optic atrophy, and it is identified by the non-specific symptom of

optic disc pallor. The central nervous system is typically not capable of these activities, whereas the peripheral nervous system has an inherent capacity for repair and regeneration. The oligodendrocytes and reactive astrocytes that highly myelinate the optic nerve's axons also express a number of proteins that prevent axonal regeneration.

4. Conflict of Interest

Author has no conflict of interest to declare.

5. Source of Funding

No funding source.

References

1. Golnik K. Nonglaucomatous optic atrophy. *Neurol Clin.* 2010;28(3):631–40.
2. Li HJ, Sun ZL, Yang XT, Zhu L, Feng DF. Exploring Optic Nerve Axon Regeneration. *Curr Neuropharmacol.* 2017;15(6):861–73.
3. Quigley H, Anderson DR. The histologic basis of optic disk pallor in experimental optic atrophy. *Am J Ophthalmol.* 1977;83(5):709–17.
4. Yu-Wai-Man P, Turnbull DM, Chinnery PF. Leber hereditary optic neuropathy. *J Med Genet.* 2002;39(3):162–9.
5. Tonari M, Matsuo J, Oku H, Sugawara J, Ikeda T, Tatsuzawa K, et al. A Case of Childhood-Onset Giant Cell Tumor that Caused Optic Nerve Atrophy in Both Eyes. *Case Rep Ophthalmol.* 2017;8(2):301–7.
6. Optic Atrophy. [Retrieved on 7 Jun 2023]. Available from: <https://my.clevelandclinic.org/health/diseases/12326-optic-atrophy>.
7. Venkatramani DV, Amula GM, Gandhi R. Optic Atrophy. *Kerala J Ophthalmol.* 2010;22(2). [Retrieved on:12 Jun 2023]. Available from: <https://www.scribd.com/document/261554682/Optic-Atrophy-major-review-March-2010-Kerala-Journal-of-Ophthalmology-Devendra-V-Venkatramani-et-al>.
8. Huizing M, Brooks BP, Anikster Y. Optic atrophies in metabolic disorders. *Mol Genet Metab.* 2005;86(1-2):51–60.

Author biography

Kameshwaran, Professor and Head

S Shameem, Final Year Student (B.Pharm)

A Saranya, Final Year Student (B.Pharm)

KP Sathish, Final Year Student (B.Pharm)

K Shanmugapriya, Final Year Student (B.Pharm)

SM Shabariraj, Final Year Student (B.Pharm)

Cite this article: Kameshwaran, Shameem S, Saranya A, Sathish KP, Shanmugapriya K, Shabariraj SM. Review on optic atrophy. *IP Int J Comprehensive Adv Pharmacol* 2023;8(3):203-205.