

Content available at: <https://www.ipinnovative.com/open-access-journals>

# IP International Journal of Comprehensive and Advanced Pharmacology

Journal homepage: <https://www.ijcap.in/>

## Review Article

# Revisiting novel interventions in melanoma

Sunil Chaudhry<sup>1,\*</sup>

<sup>1</sup>Director Solutions, Thane & Consult Edenwell Therapeutics, Mumbai, Maharashtra, India



### ARTICLE INFO

#### Article history:

Received 23-01-2023

Accepted 10-04-2023

Available online 23-05-2023

#### Keywords:

Metastatic melanoma

Immunotherapy

Targeted therapy BRAFV600

chemotherapy

Radiotherapy

Surgery

### ABSTRACT

Malignant tumor which that arises from uncontrolled proliferation of melanocytes is melanoma. Its rare tumor in India, compared to other tropical countries. Fair skin populations have higher incidences of melanoma. The relative mortality is reduced to nearly half with scrupulous use of sunscreens - SPF 50 blocks 98% of UVB rays. Melanomas are observed more in countries like Australia and New Zealand (due to actinic rays (UV B rays) of light) and thus guidelines from their ministry of health has been published. First line drugs for melanoma unresectable stage III or IV metastatic disease include Pembrolizumab and Nivolumab. Studies have shown that Pembrolizumab improved overall survival (OS) compared with ipilimumab. Ipilimumab/Nivolumab combination was significantly better than ipilimumab monotherapy. Similarly nivolumab/ipilimumab combination therapy was better than compared with ipilimumab monotherapy regardless of BRAF mutation status. Vemurafenib and Dabrafenib (Tyrosine kinase inhibitors) were developed to inhibit BRAF with mutations at V600. Dabrafenib/Trametinib or Vemurafenib/Cobimetinib combinations were better than monotherapy. Surgery remains the best option for cure in localized, invasive melanoma, with good overall survival rate.

This is an Open Access (OA) journal, and articles are distributed under the terms of the [Creative Commons Attribution-NonCommercial-ShareAlike 4.0 License](https://creativecommons.org/licenses/by-nc-sa/4.0/), which allows others to remix, tweak, and build upon the work non-commercially, as long as appropriate credit is given and the new creations are licensed under the identical terms.

For reprints contact: [reprint@ipinnovative.com](mailto:reprint@ipinnovative.com)

## 1. Introduction

Malignant transformation of melanocytes, produces melanoma. These are present where the neural crest migrate such as gastrointestinal tract and brain. The Age-standardized rate (ASR) by world is expressed per 100,000 persons, is highest in New Zealand 35.8 as compared to India 0.2- 0.3.<sup>1</sup> The 5-year relative survival rate for patients with stage 0 melanoma is 97%, compared with about 10% for those with stage IV disease.<sup>2</sup> The risk factors for melanoma are: Pigmentation where Melanocortin 1 receptor (MC1R) is a cell surface receptor is expressed, this is more expressed in fair persons, who have more sensitivity to UV light. 25% melanomas exist on preexisting nevus. History of sunburn in childhood is associated with a higher risk, patients who present other skin malignancies (basal cell

or squamous cell carcinomas or mycosis fungoides) are at higher risk of developing melanoma. Specific syndromes- such as atypical familial multiple moles and melanoma syndrome (FAMMM) or dysplastic nevus syndrome (DNS), are more prone for changes in the skin.<sup>3</sup> The average age of melanoma diagnosis is 63 years within India. Melanoma risk appears to be rising in those under the age of 40, particularly among women. The subtypes of Melanoma are: superficial spreading (SSM), nodular (NM), lentigo maligna (LM), and acral lentiginous (ALM).<sup>4</sup> Two genes have been primarily linked to familial melanoma; they are called CDKN2A (tumor suppressor gene that encodes p16), also associated with coronary artery disease and CDK4 (the gene encoding cyclin-dependent kinase 4).<sup>5</sup> Skin biopsy (Punch or shave biopsies) are performed to diagnose melanoma. Before biopsy, photographs should be taken to document the exact location of the lesion and to ensure that

\* Corresponding author.

E-mail address: [sunil.r.chaudhry@gmail.com](mailto:sunil.r.chaudhry@gmail.com) (S. Chaudhry).

the correct area is removed in wide excision. Shave biopsies are more suitable in invasive carcinomas.

The ABCDE for Melanoma s are: Asymmetry (either half are not same) irregular Border (edges are jagged), Color variance (multicolored) Diameter of  $> \frac{1}{2}$  cm, and Evolution/Elevation of the lesion over time. The mutations most often seen in the BRAF gene are V600E (70%–80%) and V600K (20%).<sup>6</sup> The Mitogen Activated Protein Kinase (MAPK) pathway plays a vital role in melanoma development. MAPK pathway consists of RAS, RAF, MEK and ERK, where the proliferative signals are generated at the cell surface receptors and through cytoplasmic signaling into the nucleus. The MAPK pathway effects the post-translational phosphorylation of apoptotic regulatory molecules like BAD, BIM, MCL-1, caspase 9 and BCL-2, thereby regulating cellular apoptosis. The PTEN (phosphatase and tensin homologue deleted from chromosome 10) gene, which is also known as MMAC1 (mutated in multiple advanced melanoma). The Akt kinase family consists of three protein kinases Akt1 (PKB $\alpha$ ), Akt2 (PKB $\beta$ ) and Akt3 (PKB $\gamma$ ), also activated in melanoma.<sup>7,8</sup>

**2. Therapy for Melanoma**

**2.1. Metastatic melanoma and first line therapy**

Immunotherapy based on immune check point inhibitors has demonstrated its superiority over chemotherapy in terms of response, PFS and OS. The 3 main first-line classes of US Food and Drug Administration–approved agents include BRAF/MEK inhibitors (dabrafenib/trametinib, vemurafenib/cobimetinib, encorafenib/binimetinib), anti–PD-1 mono-therapy (nivolumab, pembrolizumab), and combination anti–PD-1/anti–CTLA-4 therapy (nivolumab/ipilimumab).<sup>9</sup>

**Table 1:** Pivotal trials and PFS

Drug / Combination	Median PFS – months	Median OS – months	Update OS
Nivolumab	5.1	72.9 at 1yr	51.2 at 3yr
Pembrolizumab	4.1	68.4 at 1yr	32.7 at 5yr
Ipilimumab+ Nivolumab	11.5	64 at 2yr	58 % at 3yr

**Table 2:** BRAF mutantmelanomas<sup>10</sup>

Drug / Combination	Median PFS – months	Median OS – months	%Pts alive at 3yr
Dabrafenib+ Trametinib	11.1	25.9	37
Vemurafenib+ Cobimetinib	12.6	22.5	34.7
Encorafenib+ Binimetinib	14.9	33.6	47

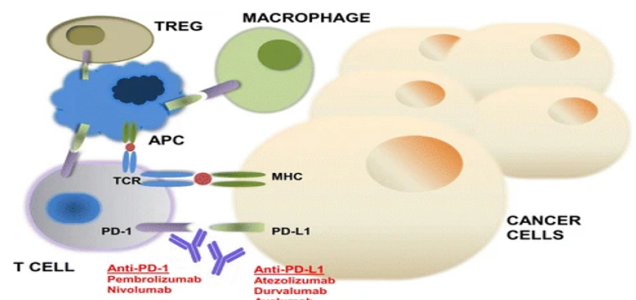
**2.2. The domain of checkpoint inhibitors**

The checkpoint inhibitors help immune system to lyse cancer cells directly. PD 1 is protein present on T cells & the class include drugs like Pembrolizumab, Nivolumab and Cemiplimab. Checkpoint inhibitors work by blocking the receptors that cancer cells use to send signals to T-cells. Monoclonal antibodies (mAbs) targeting programmed cell death protein 1 (PD-1)) have been approved for the treatment of melanoma.

PD-1 is relative of CD28 family and an inhibitory receptor expressed on activated T cells, B cells, macrophages, regulatory T cells (Tregs), and natural killer (NK) cells. This receptor has two binding ligands, PDL-1 and PDL-2 (B7 family) that are expressed on T cells, B cells.

Checkpoint proteins, such as PD-L1 on Tumor cells and PD-1 on T cells, help to keep immune responses in check. The binding of PD-L1 to PD-1 keeps immune responses in check. Blocking the binding of PD1 with immune checkpoint inhibitor allows T cells to kill tumor cells.

Pemrolizumab is indicated for treatment of unresectable or metastatic melanoma. Dose is 200 mg IV once for 3Weeks OR 400 mg once for 6 weeks weeks until disease progression or there is unacceptable toxicity. It is basically indicated for adjuvant treatment of adults with Stage IIB, IIC, or III melanoma following complete resection 200 mg IV once in 3Weeks OR 400 mg once in 6 weeks.



**Fig. 1:** Action of PD-1 inhibitors

Nivolumab as monotherapy or in combination with ipilimumab is indicated for the treatment of advanced (unresectable or metastatic) melanoma in adults. An increase in progression-free survival (PFS) and overall survival (OS) for the combination of nivolumab with ipilimumab is often reported in most trials.

The recommended dose is 1 mg/kg nivolumab in combination with 3 mg/kg ipilimumab administered intravenously every 3 weeks for the first 4 doses. This is then followed by a second phase in which nivolumab monotherapy is administered intravenously at either 240 mg every 2 weeks or at 480 mg every 4 weeks.<sup>11,12</sup>

### 2.2.1. Atezolizumab

Atezolizumab: is a fully humanized IgG1 monoclonal antibody that is engineered with a modification in the Fc domain that eliminates antibody-dependent cellular cytotoxicity to prevent depletion of T cells expressing PD-L. Atezolizumab 840 mg IV on Days 1 and 15, along with Cobimetinib 60 mg PO qDay on Days 1-21 plus vemurafenib 720 mg PO BID on Days 1-28. Mild ADRs are seen in 87 percent whereas severe or life threatening are seen in 13 percent.<sup>13</sup>

### 2.2.2. BRAF & MEK inhibitors: Dabrafenib and trametinib

Dabrafenib is an inhibitor of BRAF kinases. Trametinib is an inhibitor of mitogen-activated extracellular signal regulated kinases 1 and 2 (MEK1 and MEK2).

Dabrafenib as monotherapy or in combination with trametinib is indicated for the treatment of adult patients with unresectable or metastatic melanoma with a BRAF V600 mutation. (Stage III or IV melanoma).

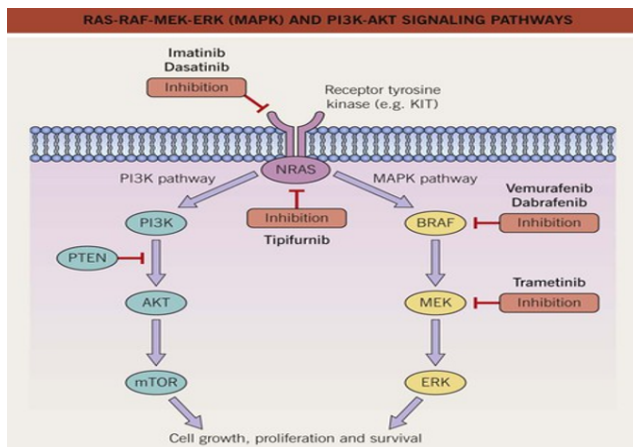


Fig. 2: Action of BRAF & MEK inhibitors

### 2.2.3. Regimens

- 1-28 day Dabrafenib 150mg BD PO and 1-28 day Dabrafenib is available as 75mg and 50mg capsules
- Trametinib 2mg OD PO. Trametinib is available as 0.5mg and 2mg tablets.<sup>14</sup>

### 2.2.4. Vemurafenib & Cobimetinib

The combination of vemurafenib and cobimetinib, as compared with vemurafenib alone, resulted in improved overall survival with increased toxicity profile. Cobimetinib and vemurafenib have shown objective response in (70%), with complete response in 21% and partial response in 49%.

Vemurafenib is taken on days 1 through 28 of each 28-day cycle. Vemurafenib is recommended dose is 960 mg (four 240-mg tablets) orally taken every 12 hours.

He it's the recommended dose of Cobimetinib is 60 mg (three 20-mg tablets) orally taken once daily. Cobimetinib is taken for the first 21 days of each 28-day cycle<sup>15</sup>

### 2.2.5. Encorafenib & Binimetinib

Encorafenib plus binimetinib was approved in 2018 for the treatment of patients with unresectable or metastatic melanoma with BRAF V600E or V600K mutations. The recommended dose of Encorafenib is 450 mg (six 75 mg capsules) once daily, when used in combination with binimetinib. The recommended dose of binimetinib is 45 mg orally twice daily<sup>16</sup>

### 2.2.6. Relatlimab

Relatlimab: is the first mAb against LAG-3. (Lymphocyte Activation Gene 3) Relatlimab reversed the T-cell inhibition. Reduces expression of multiple inhibitory receptors including PD-1, CTLA-4, LAG-3.

Formulation available as 12 mg of nivolumab and 4 mg of relatlimab. One vial of 20 mL contains 240 mg of nivolumab and 80 mg of relatlimab.

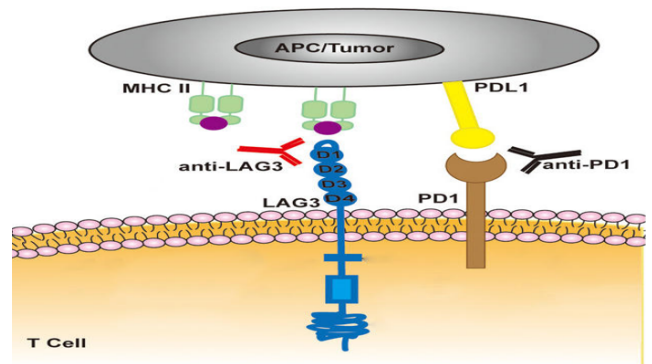


Fig. 3: Activation of LAG

The combination is used as first-line treatment of advanced (unresectable or metastatic) melanoma in adults and adolescents 12 years of age and older with tumour cell PD-L1 expression < 1%

Patients who received nivolumab and relatlimab had longer progression-free survival than patients who received nivolumab alone (10.1 months versus 4.6 months).<sup>17</sup>

Ipilimumab improves survival in advanced melanoma and can induce immune-mediated tumor vasculopathy. Addition of Bevacizumab causes VEGF blockade. Both can improve survival of metastatic melanoma.<sup>18</sup>

The national cancer Institute has approved many reserve line drugs, Listed in Table 3 (Variants):<sup>19</sup>

Treatment of metastatic melanoma with combined chemotherapy containing cisplatin, vinblastine and dacarbazine (CVD) and biotherapy using interleukin-2 and interferon-alpha, produces overall response rate of 33 Percent.<sup>20</sup>

**Table 3:**

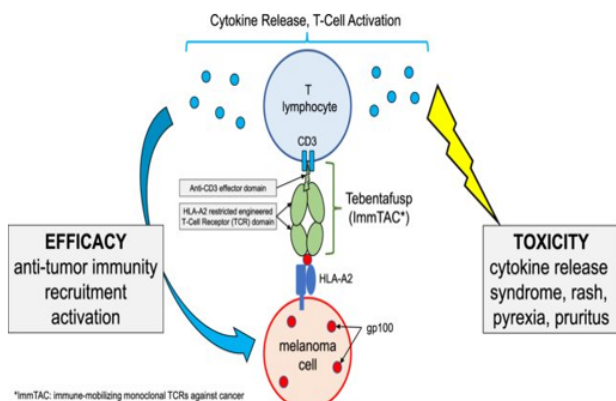
Drug	Dose	Usage
Dacarbazine - DNA synthesis inhibition by its action as a purine analog	850mg/m <sup>2</sup> , IV Infusion. Concomitant use of phenytoin and dacarbazine should be avoided since there is a risk of exacerbation of convulsions	Third Line Drug for Treatment of metastatic malignant melanoma, Stage IIIC & IV

**Table 4:**

Drug	Dose	Usage
Aldesleukin (IL2) genetically engineered from E. coli. It acts by: <ul style="list-style-type: none"> <li>• Blocks the multiplication and spread of cancer cells</li> <li>• Stimulates the development of white blood cells that attack cancer</li> </ul>	Intermittent IV: 600,000 International units (IU)/kg (0.037 mg/kg) every 8 hours for 14 doses	Stage III & IV Melanoma

**Table 5:**

Drug	Dose	Usage
Tebentafusp	20 mcg intravenously on Day 1, 30 mcg intravenously on Day 8, 68 mcg intravenously on Day 15, and 68 mcg intravenously once every week thereafter	HLA-A*02:01-positive adult patients with unresectable or metastatic uveal melanoma.



**Fig. 4:** Mode of action of tebentafusp

Tebentafusp-tebn is a T cell–redirecting bispecific fusion protein that redirects the immune system to target gp100-expressing uveal melanoma tumor cells.<sup>21</sup>

**Table 6:**

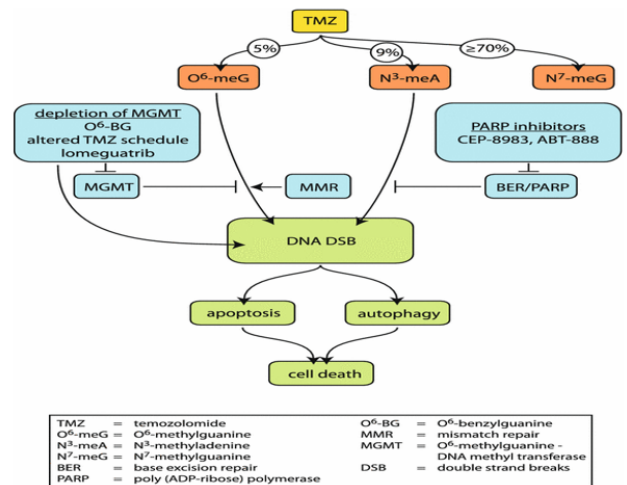
Drug	Dose	Usage
Talimogene laherparepvec is an attenuated herpes simplex virus type-1 (HSV-1) derived by functional deletion of 2 genes	Up to 4 mL of IV slow infusion	local treatment of unresectable cutaneous, subcutaneous, and nodal lesions in patients with melanoma recurrent after initial surgery, III B, IIIC & IV stages.

**Table 7:**

Drug	Dose	Usage
Temozolomide (TMZ)- DNA methylating agent	use temozolomide at a dose of 200 mg/m <sup>2</sup> orally for 5 days every 4 weeks	TMZ is very well tolerated and has an advantage in terms of improving the quality of life of patients with metastatic melanoma., stage IV

**2.3. Mode of action of Temozolomide**

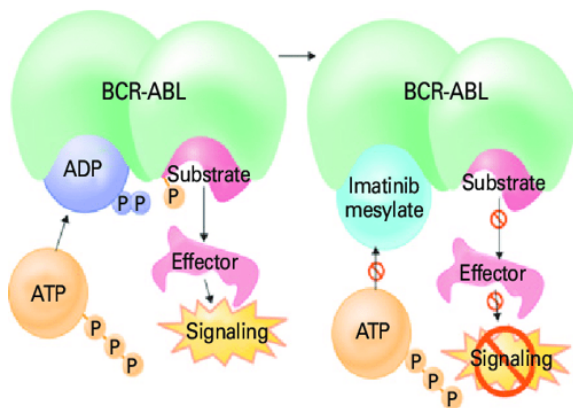
Temozolomide, is a prodrug which is rapidly hydrolysed to 5-(3-methyltriazen-1-yl)-imidazole-4-carboxamide (MTIC). MTIC performs alkylation of DNA, leading to DNA double strand breaks and apoptosis.<sup>22</sup>



**Fig. 5:** Action of temozolomide

**Table 8:**

Drug	Dose	Usage <sup>23</sup>
Tamoxifen with Dacarbazine	Tamoxifen was administered orally at a dose of 20 mg per square meter per day,	Improvement of response (28% vs 12%,) and survival (48 weeks vs 29 weeks)
Fotemustine/ Treosulfan /gemcitabine	Induction cycle 100 mg/m <sup>2</sup> Treosulfan 5 g/m <sup>2</sup> i.v. day 1 Gemcitabine 1 g/m <sup>2</sup> i.v. day 1 Repeat every 3 weeks	Advanced uveal melanoma
Imatinib	400mg / day, continuously	Imatinib treatment for advanced melanoma with C – Kit mutations

**Fig. 6:** Action of imatinib.<sup>24–27</sup>

The yearly cost of drugs used in melanoma is expensive and leads to financial burden in most of the treated patients. Patients can benefit if they source drug from manufacturers or get themselves enrolled into clinical trials.

### 3. Radiotherapy

Radiotherapy is useful in recurrent or metastatic melanoma. Radiation therapy is usually reserved for high-risk or advanced cases of melanoma where surgery is not possible or may be complicated. More than 85% complete response rate can be seen after irradiation of small-size (i.e.  $\leq 1$  cm in diameter) cutaneous melanoma, the frequency of complete response is less than 30% in melanoma of 5 cm in diameter or larger. In palliative radiotherapy, smaller number of higher daily doses is usually employed (4-8 Gy/fx). Radiotherapy can be more effective when delivered as radiosurgery or when combined with hyperthermia, in early melanomas and in desmoplastic melanoma or in cases of recurrences. General side effects of radiation

therapy include skin irritation and infections, and sometimes fatigue.<sup>28</sup>

### 4. Surgery

Surgery remains the best option for cure in localized, invasive melanoma, with an overall 5-year survival rate of 92%. Therapeutic lymphadenectomy is the preferred treatment in patients with regional clinical lymph node involvement from melanoma. Mohs surgery is done by where the skin (including the melanoma) is removed in very thin layers. Wide local excision (WLE) of melanoma is to obtain local control by removing the (3.0 cm) primary tumor as well as the subcutaneous lymphatics.<sup>29</sup>

### 5. Conclusion

Malignant melanoma, an aggressive tumor, is which is rare in India and constitutes 0.3% of all malignancies. Risk factors for melanoma are excessive UV exposure, poor immune system, many moles which can be of larger size, people with skin cancer history, fair skinned people, and genetically predisposed persons. Therapy of melanoma is stage dependent, as per American Cancer Society. NCCN Guidelines, also suggest similar line of treatment.

**Table 9:**

Stage	Intervention
Stage 0	Imiquimod cream Radiation therapy Surgery.
Stage I	Sentinel lymph node biopsy immune checkpoint inhibitors or targeted therapy drugs (in cases of BRAF gene mutation)
Stage II	Sentinel lymph node biopsy Pembrolizumab after surgery
Stage III	Wide excision of the primary tumor along with lymph node dissection. Adjuvant treatment with immune checkpoint inhibitors or with targeted therapy drugs (Braf mutations)
Stage IV	<ul style="list-style-type: none"> <li>• Pembrolizumab or Nivolumab</li> <li>• Nivolumab with relatlimab</li> <li>• Nivolumab or Pembrolizumab, with Ipilimumab Skin tumors or enlarged lymph nodes causing symptoms can often be removed by surgery or treated with radiation therapy.</li> </ul>

The nivolumab and ipilimumab combination arm resulted in higher response rates, and progression-free survival (PFS), and overall survival. Combination therapies demonstrate superior results than monotherapy alone, without increasing adverse events significantly.

### 6. Conflicts of Interests

The authors have no financial interests or conflicts of interests.


## 7. Source of Funding

None.

## References

- Matthews NH, Li WQ, Qureshi AA, Weinstock M, Eunyoung C. Epidemiology of Melanoma; 2017. Available from: <https://exonpublications.com/index.php/exon/article/view/168/426>.
- Heistein JB, Acharya U, Mukkamalla SKR, ; ; . Malignant Melanoma. Treasure Island (FL): StatPearls Publishing; 2022.
- Conforti C, Zalaudek I. Epidemiology and Risk Factors of Melanoma: A Review. *Dermatol Pract Concept*. 2021;11(Suppl 1):e2021161. doi:10.5826/dpc.11S1a161S.
- Hernandez LE, Frech FS, Mohsin N, Dreyfuss I, Nouri K. Nodular Melanoma: A Review of Pathogenesis, Presentation, Diagnosis, and Treatment. *J Dermatol Skin Sci*. 2021;3(3):25–30.
- Potrony M, Badenas C, Aguilera P, Puig-Butille JA, Carrera C, Malvehy J, et al. Update in genetic susceptibility in melanoma. *Ann Transl Med*. 2015;3(15):210. doi:10.3978/j.issn.2305-5839.2015.08.11.
- Wohltmann W, Servey J. Melanoma: An FP's guide to diagnosis and management. *J Fam Pract*. 2021;70(6):271–8. doi:10.12788/jfp.0233.
- Madhunapantula SV, Madhunapantula GP. Therapeutic Implications of Targeting AKT Signaling in Melanoma. *Enzyme Res*. 2011;p. 327923. doi:10.4061/2011/327923.
- Inamdar GS, Madhunapantula SRV, Robertson GP. Targeting the MAPK Pathway in Melanoma: Why some approaches succeed and other fail. *Biochem Pharmacol*. 2010;80(5):624–37. doi:10.1016/j.bcp.2010.04.029.
- Gibney GT, Michael B. Choice of first-line therapy in metastatic melanoma. *Cancer*. 2019;25(5):666–9. doi:10.1002/cncr.31774.
- Majem M, Manzano JL, Marquez-Rodas I, Mujika K, Muñoz-Couselo E, Pérez-Ruiz E, et al. SEOM clinical guideline for the management of cutaneous melanoma (2020). *Clin Transl Oncol*. 2021;23(5):948–60. doi:10.1007/s12094-020-02539-9.
- Granier C, Guillebon ED, Blanc C, Roussel H, Badoual C, Colin E, et al. Eric Tartour, Mechanisms of action and rationale for the use of checkpoint inhibitors in cancer. *ESMO Open*. 2017;2(2):e000213. doi:10.1136/esmoopen-2017-000213.
- Agrawal S, Feng Y, Roy A, Kollia G, Lestini B. Nivolumab dose selection: challenges, opportunities, and lessons learned for cancer immunotherapy. *J Immunother Cancer*. 2016;4:72. doi:10.1186/s40425-016-0177-2.
- Akinleye A, Rasool Z. Immune checkpoint inhibitors of PD-L1 as cancer therapeutics. *J Hematol Oncol*. 2019;12(1):92. doi:10.1186/s13045-019-0779-5.
- Australian Public Assessment Report for Trametinib and Dabrafenib. TGA Health Safety Regulation; 2018. Available from: <https://www.tga.gov.au/sites/default/files/auspar-trametinib-dabrafenib-181108.pdf>.
- Ascierto PA, Dréno B, Larkin J, Ribas A, Liskay G, Maio M, et al. 5-Year Outcomes with Cobimetinib plus Vemurafenib in BRAFV600 Mutation-Positive Advanced Melanoma: Extended Follow-up of the coBRIM Study. *Clin Cancer Res*. 2019;27:5225–35. doi:10.1158/1078-0432.CCR-21-0809.
- Davis J, Wayman M. Encorafenib and Binimetinib Combination Therapy in Metastatic Melanoma. *J Adv Pract Oncol*. 2022;13(4):450–5. doi:10.6004/jadpro.2022.13.4.7.
- Hussein A, Tawbi. Relatlimab and Nivolumab versus Nivolumab in Untreated Advanced Melanoma. *N Engl J Med*. 2022;386:24–34.
- Hodi FS, Lawrence D, Lezcano C, Wu X, Zhou J, Sasada T, et al. Bevacizumab plus ipilimumab in patients with metastatic melanoma. *Cancer Immunol Res*. 2014;2(7):632–42. doi:10.1158/2326-6066.CIR-14-0053.
2015. Available from: <https://www.uhs.nhs.uk/Media/UHS-website-2019/Docs/Chemotherapy-SOPs1/Skincancer/SkinDacarbazineVer1.pdf>.
- Aldesleukin (IL-2, Proleukin or interleukin 2). Available from: <https://www.cancerresearchuk.org/about-cancer/treatment/drugs/aldesleukin>.
- Nathan P, Hassel JC, Rutkowski P, Baurain JF, Butler MO, Schlaak M, et al. Overall Survival Benefit with Tebentafusp in Metastatic Uveal Melanoma. *N Engl J Med*. 2021;385:1196–206. doi:10.1056/NEJMoa2103485.
- Ferrucci PF, Pala L, Conforti F, Cocorocchio E. Talimogene Laherparepvec (T-VEC): An Intralesional Cancer Immunotherapy for Advanced Melanoma. *Cancers (Basel)*. 2021;13:1383. doi:10.3390/cancers13061383.
- Li RH. Temozolomide for Treating Malignant Melanoma. *J Coll Physicians Surg Pak*. 2015;25(9):680–8.
- O'Day S, Kim CJ, Reintgen DS. Metastatic melanoma: chemotherapy to biochemotherapy. *Cancer Control*. 2002;9:31–8. doi:10.1177/107327480200900105.
- Garbe C, Peris K, Hauschild A, Saiag P, Middleton M, Bastholt L, et al. Diagnosis and treatment of melanoma. European consensus-based interdisciplinary guideline e Update. *Eur J Cancer*. 2016;63:201–17. doi:10.1016/j.ejca.2016.05.005.
- Wei X, Mao L, Chi Z, Chi Z, Sheng X, Cui C, et al. Efficacy Evaluation of Imatinib for the Treatment of Melanoma: Evidence From a Retrospective Study. *Oncol Res*. 2018;27(4):495–501. doi:10.3727/096504018X15331163433914.
- Mittal A, Pushpam D, Bakhshi S. Management of advanced melanoma in the current era: A medical oncology perspective for the Indian scenario. *Natl Med J India*. 2020;2:89–98. doi:10.4103/0970-258X.310984.
- Rogers SJ, Puric E, Eberle B, Datta NR, Bodis SB. Radiotherapy for Melanoma: More than DNA Damage. *Dermatol Res Pract*. 2019;doi:10.1155/2019/9435389.
- Vecchiato A, Mocellin S, Fiore PD, Tosti G, Ascierto PA, Corradin MT, et al. The surgical treatment of non-metastatic melanoma in a Clinical National Melanoma Registry Study Group (CNMR): a retrospective cohort quality improvement study to reduce the morbidity rates. *BMC Cancer*. 2021;21:8. doi:10.1186/s12885-020-07705-4.

## Author biography

Sunil Chaudhry, Director Solutions Thane  <https://orcid.org/0000-0002-5863-3025>

**Cite this article:** Chaudhry S. Revisiting novel interventions in melanoma. *IP Int J Comprehensive Adv Pharmacol* 2023;8(2):98-103.