

Content available at: <https://www.ipinnovative.com/open-access-journals>

IP International Journal of Comprehensive and Advanced Pharmacology

Journal homepage: <https://www.ijcap.in/>

Case Report

Oxaliplatin triggered hypersensitivity reactions in colorectal cancer patients: Case report

Ayushreeya Banga¹, Khadga Raj Aran^{2*}¹Dept. of Pharmacy Practice, ISF College of Pharmacy, Moga, Punjab, India²Dept. of Pharmacology, ISF College of Pharmacy, Moga, Punjab, India

ARTICLE INFO

Article history:

Received 04-08-2024

Accepted 12-09-2024

Available online 05-10-2024

Keywords:

Colorectal cancer

Oxaliplatin

Adenocarcinoma

ABSTRACT

Colorectal cancer stands as a significant global health concern, encompassing adenocarcinoma of both the colon and rectum. Recognized risk factors include advancing age and medical history of inflammatory bowel conditions like Crohn's disease or ulcerative colitis. Oxaliplatin, a platinum-based chemotherapy agent, serves as the frontline treatment for colorectal cancer due to its cytotoxic effects on cancerous cells. However, its use is not without complications, as hypersensitivity reactions can occur, posing challenges in patient management. This case report discusses two instances where patients undergoing chemotherapy for colorectal cancer developed grade two hypersensitivity reactions following oxaliplatin administration, the Naranjo probability scale was used to analyze the causation of the adverse drug reactions (ADRs), and a score of 6 was obtained, indicating oxaliplatin as a probable cause of the hypersensitivity reactions. In both cases, treatment was promptly halted upon manifestation of symptoms, and patients were administered intravenous steroids along with anti-histamines. This intervention resulted in significant improvement in the patients' conditions. Both genders are equally susceptible to such reactions, emphasizing the need for gender-neutral awareness and precautionary measures among medical practitioners. This case report serves as a reminder of the potential adverse effects associated with oxaliplatin therapy in colorectal cancer patients. Heightened awareness among healthcare professionals regarding the risk of hypersensitivity reactions is imperative to ensure timely detection and appropriate management, thereby optimizing patient outcomes. Consequently, while giving oxaliplatin to cancer patients, healthcare professionals need to use extreme caution.

This is an Open Access (OA) journal, and articles are distributed under the terms of the [Creative Commons Attribution-NonCommercial-ShareAlike 4.0 License](https://creativecommons.org/licenses/by-nc-sa/4.0/), which allows others to remix, tweak, and build upon the work non-commercially, as long as appropriate credit is given and the new creations are licensed under the identical terms.

For reprints contact: reprint@ipinnovative.com

1. Introduction

Colorectal cancer (CRC) is one of the top five causes of death globally and additionally the third most common kind of cancer overall, with approximately 700,000 deaths annually attributed to this disease (Afolabi H 2022 e.tal).¹ It stands as the second most common cancer in women (9.2%) and the third most common in men (10%), representing a significant global health burden (Mármol I 2017 e.tal).² Advanced age remains the most significant risk factor

for CRC, while certain personal traits and behaviors can also increase susceptibility to developing polyps or colon cancer (Macrae FA 2017 e.tal).³ Intrinsic risk factors, such as a history of colorectal cancer or inflammatory bowel disease (IBD), particularly ulcerative colitis and Crohn's disease, further elevate the risk of CRC development. The predominant histological subtype of colorectal cancer (CRC) is adenocarcinoma of both the rectum and colon, which is distinguished by the conversion of normal colonic and rectal epithelium into adenomatous intermediates, which are precancerous lesions which eventually progress to adenocarcinoma. This transformation typically occurs over

* Corresponding author.

E-mail address: bishalarann@gmail.com (K. Raj Aran).

a span of 10 to 15 years and involves genetic mutations (Alzahrani SM 2021e.tal).⁴ Patients with CRC typically undergo treatment with a combination of biological therapy and cytotoxic agents. A common component of primary hospice treatment is fluoropyrimidines, such as 5-fluorouracil (5-FU), either alone or in combination with leucovorin (LV), alongside other agents like oxaliplatin or irinotecan (Vodenkova S 2020 e.tal).⁵

The 1, 2-diaminocyclohexane (DACH) carrier is a ligand found in the platinum-based chemotherapy drug oxaliplatin, is utilized in approximately 80% of CRC cases as a primary chemotherapeutic agent (Misset JL 2000 e.tal). Its cytotoxic activity primarily stems from the DACH group, leading to DNA damage within cancer cells, ultimately resulting in cell death by inhibiting DNA and RNA synthesis and activating the immune system (Wang D 2005 e.tal).⁶ However, oxaliplatin administration can also precipitate adverse drug reactions, including renal and hepatic dysfunction, thrombosis, gastrointestinal disturbances (nausea, vomiting, diarrhea), alopecia, anemia, and neutropenia (Baldo BA 2013 e.tal).⁷ This case report highlights a rare adverse reaction induced by oxaliplatin and underscores the importance of vigilant monitoring and consideration of various factors during patient treatment. The presented case, originating from the capital city of India, serves as a noteworthy addition to the existing literature on oxaliplatin-induced hypersensitivity reactions

resection (LAR) in January 2023, involving excision of the recurrent tumor, distal left ureter, and a segment of the mid ileum. Following LAR, the patient received multiple cycles of chemotherapy, including CAPIRI (capecitabine and irinotecan) in combination with VECTIBIX. However, disease progression was observed on a PET scan performed in November 2023, revealing metabolically active metastases to bilateral lungs, liver, serosal, and peritoneal deposits. As a result, the patient was admitted for further chemotherapy in March 2024, undergoing cycle 3 of treatment.

This case underscores the challenges associated with managing metastatic colorectal cancer and highlights the importance of a multidisciplinary approach to treatment. Additionally, it emphasizes the need for ongoing research to optimize therapeutic strategies and improve patient outcomes in advanced colorectal cancer cases. During treatment, the patient had a grade II hypersensitivity response, which included facial puffiness and generalized urticaria. The treatment was immediately halted, and the patient was given intravenous steroids with anti-histamines because the patient’s condition had improved.

1.2. Case 2

A female patient, 47 years of age, was hospitalized for a follow-up after undergoing chemotherapy. She had been diagnosed with stage II adenocarcinoma of the mid-rectum and had received the fourth cycle of oxaliplatin treatment on December ‘23. In January 2024, she underwent a procedure known as low anterior resection (LAR) with colorectal anastomosis, accompanied by diversion loop transverse colostomy.

Earlier, in 2023, a PET scan had revealed malignant circumferential mural thickening involving the rectum, which exhibited metabolic activity and heterogeneous enhancement. Additionally, a few small, non-FDG avid perirectal lymph nodes were detected, indicating possible metastasis. However, a subsequent scan in October 2023 indicated that the disease’s severity and extent had significantly decreased. During her hospitalization for chemotherapy, the patient experienced a grade II hypersensitivity reaction, characterized by generalized urticaria and facial swelling, following exposure to oxaliplatin. Chemotherapy was promptly halted, and the patient was administered intravenous steroids and antihistamines to alleviate her symptoms. Subsequently, she responded well to the treatment and was discharged in a stable condition.

2. Causality Assessment of the ADR- with the Help of Naranjo Scale

Using the Naranjo scale for adverse reactions, the ADR mentioned in the case reports was evaluated. The Naranjo

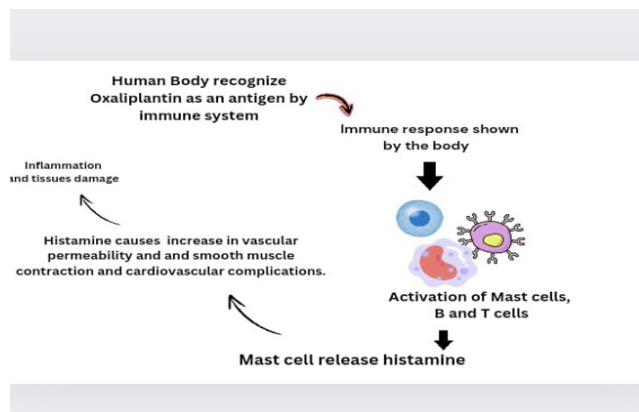


Figure 1: Pathophysiology of oxaliplatin induce hypersensitivity reaction.

1.1. Case 1

The 43-year-old male patient with sigmoid colon metastatic adenocarcinoma is the subject of this case report, which details his treatment. The patient underwent post-surgery adjuvant chemotherapy with CAPOX (capecitabine and oxaliplatin) following second-stage colon cancer resection on July 9, 2021. Despite initial treatment, disease recurrence occurred in 2022, leading to a subsequent low anterior

Table 1: Probability category score: Doubtful = 0, Possible = 1-4, Probable = 1-4, and Definite = 9 or above.

Sr.no	Questions	Yes	No	Do not know	Total score
1.	Are there previous conclusive reports on this reaction?	+1	0	0	+1
2.	Did the adverse event appear after the suspected drug was administered?	+2	-1	0	+2
3.	Did the adverse reaction improve when drug was discontinued or a specific antagonist was administered?	+1	0	0	+1
4.	Did the adverse event reappear when the drug was re-administered?	+2	-1	0	0
5.	Are there alternative causes that could on their own have caused the reaction?	-1	+2	0	+1
6.	Did the reaction reappear when a placebo was given?	-1	+1	0	0
7.	Was the drug detected in blood in concentrations known to be toxic?	+1	0	0	0
8.	Was the reaction more severe when the dose was increased or less severe when the dose was increased?	+1	0	0	0
9.	Did the patient have a similar reaction to the same or similar drugs in any previous exposure?	+1	0	0	0
10.	Was the adverse event confirmed by any objective evidence?	+1	0	0	+1
Total					+6

probability score of six was recorded for this case report, as seen in Table 1. This indicates a probable relationship between the hypersensitivity reaction the patient experienced and oxaliplatin administered to the patient.

3. Discussion

Hypersensitivity reactions to oxaliplatin are relatively rare occurrences, but their incidence tends to increase with repeated exposure to the drug. Typically, these reactions manifest after 4 to 6 courses of treatment (Haynes D 2020 et al).⁸ Highlighted that oxaliplatin hypersensitivity reactions may be under-diagnosed, especially when symptoms are mild, and estimated the incidence to be around 12%. These reactions can be categorized into two main types: anaphylactic reactions and idiosyncratic reactions. Anaphylactic reactions, which are classified as type

I hypersensitivity reactions, typically occur within minutes of drug administration in patients with previous exposure. Symptoms may include facial swelling, bronchospasm, hypotension, tachycardia, itching, and redness. These symptoms are triggered by the release of mast cell and basophil mediators following IgE binding (Sriaroon P 2021 et al).⁹

On the other hand, idiosyncratic reactions are not antibody-related and may have a delayed onset. Symptoms can include fever, chills, abdominal pain, nausea, and diarrhea, sometimes accompanied by hypotension. These effects are considered to be induced by the production of cytokines such as interleukin 6, also known as IL-6, and tumor necrosis factor, or TNF, from the cells. In the discussed case, the patient experienced hypotension, dyspnea, itching, and redness immediately after the start of the third cycle infusion of oxaliplatin, consistent with an anaphylactic reaction. Despite premedication with steroids and antihistamines, the same symptoms recurred upon retrieval of oxaliplatin, indicating a severe reaction. Patients who experience severe reactions are unlikely to tolerate further oxaliplatin therapy.

It is crucial to remain vigilant for hypersensitivity reactions to oxaliplatin, even in cases where symptoms are mild, such as fever. Although the overall incidence of these reactions is low, careful monitoring for the development of both anaphylactic and idiosyncratic reactions is essential to ensure patient safety and appropriate management.

4. Conclusion

In conclusion, managing hypersensitivity reactions induced by oxaliplatin in colorectal cancer treatment demands careful monitoring and prompt intervention. In the cases discussed, hypersensitivity reactions were effectively identified and managed through cessation of therapy and administration of anti-histamines and steroids. While supportive care suffices for most adverse drug reactions, severe cases necessitate discontinuation of oxaliplatin therapy and consideration of alternative treatments. Healthcare providers must remain vigilant regarding patient responses to therapy and be prepared to provide immediate medical assistance when encountering undesirable reactions.

5. Patient Consent Statement

The authors certify that they have obtained appropriate patient consent forms for use of patient’s data obtained but they were uncomfortable getting photographed, hence refused to give consent on clicking/sharing any kind of pictures even with confirmation regarding their identity being confidential.

6. Data Sharing Statement

The data supporting this study's conclusions can be assessed from the corresponding author upon justifiable request. Accessibility to the data is restricted from the public domain due to privacy or ethical constraints.

7. Author Contributions

All authors included in this study contributed in the analysis of data, drafting or revision of the article, have concurred on the publication journal to it shall be submitted, provided a final affirmation on the final version to be published, and commit to take responsibility accountable for all facets of the work.

8. Source of Funding

This study received no specific grant/financial support from any sponsor/funding agency in the public, commercial, or non-profit sectors.

9. Conflict of Interest

None.

10. Acknowledgement

We are thankful to our patients for their support and cooperation.


References

1. Afolabi H, Salleh SM, Zakaria Z, Abdulrahman AS, Nafi M. The Prediction of Survival Outcome and Prognosis Factor in Association with Comorbidity Status in Patients with Colorectal Cancer: A

- Research-Based Study. *InHealthcare*. 2022;10(9):1693.
2. Mármol I, Sánchez-De-Diego C, Dieste P, Cerrada A, Yoldi R. Colorectal carcinoma: a general overview and future perspectives in colorectal cancer. *Int J Mol Sci*. 2017;18(1):197.
3. Macrae FA, Goldberg RM, Seres D. Colorectal Cancer: Epidemiology, Risk Factors, and Prevention. *Cancers*. 2016;16(8):1530.
4. Alzahrani SM, Doghaither A. General Insight into cancer: An overview of colorectal cancer. *Mol Clin Oncol*. 2021;15(6):1–8.
5. Vodenkova S, Buchler T, Cervena K, Veskrnova V, Vodicka P, Vymetalkova V. 5-fluorouracil and other fluoropyrimidines in colorectal cancer: Past, present and future. *Pharmacol Therap*. 2020;206:107447.
6. Wang D, Lippard SJ. Cellular processing of platinum anticancer drugs. *Nat Rev Drug Discov*. 2005;4:307–27.
7. Baldo BA, Pham NH. Adverse reactions to targeted and non-targeted chemotherapeutic drugs with emphasis on hypersensitivity responses and the invasive metastatic switch. *Cancer Metastasis Rev*. 2013;32:723–61.
8. Haynes D, Ortega-Loayza AG. Adverse cutaneous reactions to chemotherapeutic drugs. *Clin Dermatol*. 2020;38(6):712–40.
9. Sriaroon P, Ledford DK. Allergic and NonAllergic Systemic Reactions including Anaphylaxis, An Issue of Immunology and Allergy Clinics of North America, E-Book: Allergic and NonAllergic Systemic Reactions including Anaphylaxis, An Issue of Immunology and Allergy Clinics of North America. In: and others, editor. *View all Allergy & Clinical Immunology titles*. Elsevier Health Sciences; 2021. p. 240.

Author biography

Ayushreeya Banga, Research Scholar

Khadga Raj Aran, Associate Professor  <https://orcid.org/0000-0002-2450-2975>

Cite this article: Banga A, Raj Aran K. Oxaliplatin triggered hypersensitivity reactions in colorectal cancer patients: Case report. *IP Int J Comprehensive Adv Pharmacol* 2024;9(3):215-218.