

Content available at: <https://www.ipinnovative.com/open-access-journals>

IP International Journal of Comprehensive and Advanced Pharmacology

Journal homepage: <https://www.ijcap.in/>

## Case Report

# Type- II delayed hypersensitivity reaction by processed elephant foot yam (Amorphophallus paeoniifolius)

Abhishek Sharma<sup>1,\*</sup>, Gulnaz Bano<sup>2,\*</sup>, Ayushi<sup>3</sup>

<sup>1</sup>Dept. of Quality Control & Assurance, Hakeem Abdul Hameed Centenary Hospital & HIMSR, Jamia Hamdard, New Delhi, India

<sup>2</sup>Dept. of Pharmacology, School of Pharmaceutical Education and Research, Jamia Hamdard, New Delhi, India

<sup>3</sup>Dept. of Pharmacy, Delhi Institute of Pharmaceutical Sciences & Research University, Pushp Vihar, New Delhi, India



### ARTICLE INFO

#### Article history:

Received 25-01-2022

Accepted 31-01-2022

Available online 05-03-2022

#### Keywords:

Jimikand  
food allergy  
rashes  
purities  
Nutraceuticals

### ABSTRACT

All types of food and food products carry potential of allergies in human. The property of allergic tendency is being carried through generations to generation in their genomic sequence. The allogenic behaviour of body towards all types of nutraceuticals and ingredients raises huge concern among dermatologist to manage patient. We here have reported a very rare adverse event following ingestion of common staple food of elephant foot yam. However, we suggest that all types of tuberous roots and vegetables should undergo pre-treatment/washing before its consumption for the removal of toxic chemicals and impurities.

This is an Open Access (OA) journal, and articles are distributed under the terms of the [Creative Commons Attribution-NonCommercial-ShareAlike 4.0 License](https://creativecommons.org/licenses/by-nc-sa/4.0/), which allows others to remix, tweak, and build upon the work non-commercially, as long as appropriate credit is given and the new creations are licensed under the identical terms.

For reprints contact: [reprint@ipinnovative.com](mailto:reprint@ipinnovative.com)

## 1. Introduction

Amorphophallus paeoniifolius (Dennst.) Nicolson (Araceae) called as elephant foot yam has originally come from Southeast Asia. It is considered to be a staple food in India, Indonesia, Philippine, Bangladesh, China and some other Southeast Asian countries. In India, it is commonly called as 'jimmikand' or 'suweg'. It grows quite well in aerated coarse textured soils with adequate rainfall. It is known to have numerous medicinal properties and thus so possesses potentials of an herbal drug. It is used in many ayurvedic preparations to treat several ailments like tumors, cough, elephantiasis, haemorrhage, seminal weakness, amenorrhea, asthma fatigue and anemia.<sup>1</sup> It acts as a potent agent in gastrointestinal abnormalities like vomiting, constipation, hemorrhoids etc.<sup>1,2</sup> Suweg contains high percentages of flavonoids and alkaloids which accounts for its antimicrobial activity along with

its antifungal and antihelminthic effects.<sup>3</sup> Yuzammi et al calculated the nutrient percentages in suweg of Java. It was found to have highest carbohydrates and proteins content with lowest fat concentration. Phosphorus and calcium were the minerals found in largest quantity.<sup>4</sup> Even though after the introduction of rice and cereals, use of suweg became unpopular, it is still considered as a sub dietary food in many countries. Since it is a common food, it is usually cooked by steaming or boiling and is rarely consumed in its raw form.

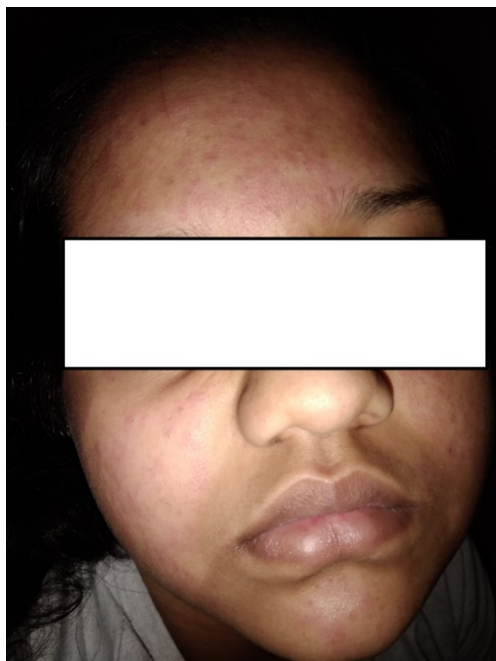Allergic reactions to elephant foot yam are very rare in both clinics and literature especially when consumed in a cooked form. Even though Amorphophallus paeoniifolius has enormous ethno-medicinal use in several ailments and pharmacological findings, still oral toxicities been reported in patients when they consumed it in a raw form. However, allergic reactions due to cooked elephant foot yam have not been published much. Here, we will discuss a case study of a female who showed allergic reactions on her skin externally after she ate cooked elephant foot yam.

\* Corresponding authors.

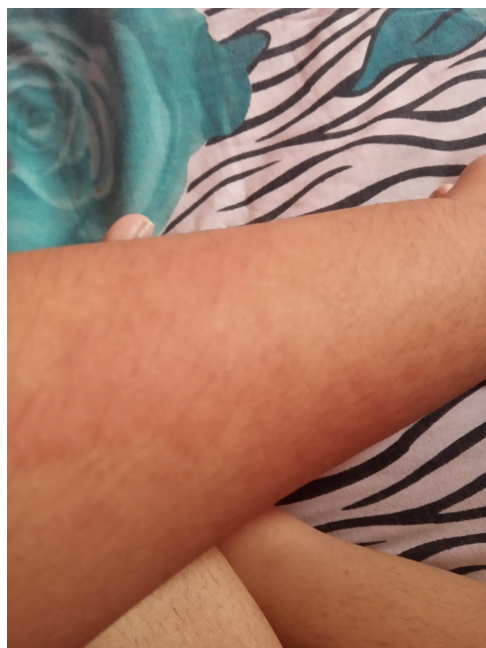E-mail address: [Scientist.abhi12@gmail.com](mailto:Scientist.abhi12@gmail.com) (A. Sharma).

## 2. Case Study

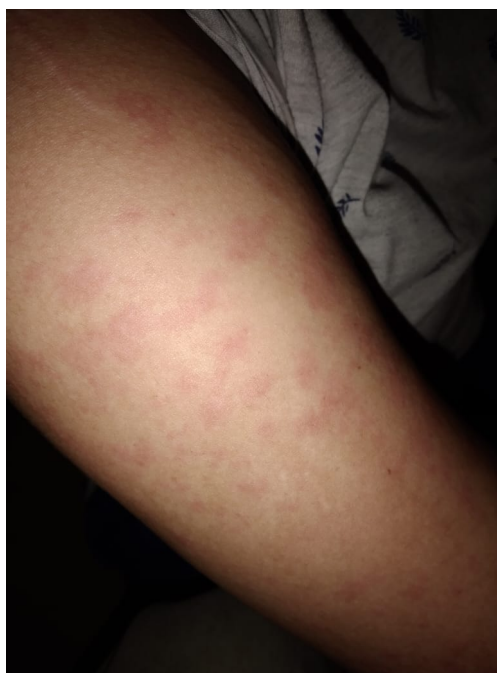A 16 years old Asian female with body weight 40 kg, height 5 feet, 3 inch started experiencing rashes, wheals-flares on upper and lower extremities in the evening 4:00 PM after consuming cooked yam (jimmikand) at 12:00 PM.



**Fig. 1:** Pruritis and rashes on forehead and face



**Fig. 2:** Rashes on arms



**Fig. 3:** Rashes and pruritus on lower extremities

The rashes gradually progressed to arm and trunk region by 6:00 PM. On Examination, Blood pressure, pulse rate was normal. Anti-histaminic treatments were given at the local OPD. The event subsided thereafter. The next day at 12:00 PM, again the rashes reappeared with itching and redness over upper and lower extremities. By 9:00 PM, at night, the rashes spread to her face with sensation of burning and pruritus. Patient was rushed to hospital, where she was given Inj. Hydrocortisone 100 mg STAT, Inj. Chlorpheniramine maleate 10 mg/ml. Emergency discharge treatment included Tab Levocitrizine 5 mg once a day at bed time for 2 days.

## 3. Discussion

Elephant foot yam has been well known for its acrid taste and possible injurious potentials when consumed in a raw form. Previously, it was determined that the reason for such reactions is the presence of calcium oxalate crystals on its surface. Koni et al. confirmed through his studies that calcium oxalate which is insoluble in nature was produced after a chemical reaction of oxalate and calcium thereby decreasing calcium absorption.<sup>5</sup>

The major cause of acidity in elephant foot yam has been associated with calcium oxalate.<sup>5</sup> Consumption of higher quantities of calcium oxalate might affect people with allergies and may even cause death if 50mg in concentration.<sup>6</sup> However, it was stated that calcium oxalate could be removed by several treatments like dicing, soaking in saline water, drying and cooking.<sup>7</sup>

Calcium oxalate crystals can be divided into five categories (crystal sand, raphides, druse, styloid, prismatic) based on their shape and morphology.<sup>8</sup> They are considered good for calcium regulation, plant protection, tissue support and detoxification of heavy metals. Upon tissue contact it gets penetrated causing ejector cells to release a protein called protease which further leads to tissue swelling and damage.<sup>9</sup>

Injuries on exposure to calcium oxalate crystals of elephant foot yam have been reported in the past. V. Ceretto in 2018 wrote a case study in which a 55 year old Asian female developed oral pain, swelling and numbness after consuming stir fried elephant root. This was a case of acute oral toxicity.<sup>10</sup> In one report, around 200 people exposed to Araceae developed toxic symptoms but were all very mild.<sup>11</sup> Mostly allergies related to oral mucosa were reported majorly followed by pruritus, erythema, and wheal on external skin and hands.

In our study, the female experiences type- II delayed hypersensitivity reactions and the possible reason for the development of these allergic reactions in the female can be the presence of calcium oxalate crystals. Since, nothing abnormal was observed in her diagnostic reports; the possible reason for the anaphylaxis can be based on previous findings. Pharmaceutical treatments with little evidence of efficacy that can currently be used are corticosteroids and most importantly anti-histaminergic drugs. Therefore the female was given anti histaminic treatment of levocitrizine and doses of hydrocortisone and chlorpheniramine maleate.

#### 4. Ethics Approval

Ethics committee approval not sought as there is no disclosure of patient details. However, Informed consents was taken by the volunteer.

#### 5. Source of Funding

None.


#### 6. Conflict of Interest

The author declares that there is no Conflict of interest.

#### References

1. Nair RV. Indian Medicinal Plants. *Madras: Orient*. 1993;3:118–22.
2. Dey YN, Ota S, Srikanth N, Jamal MWM. A phytopharmacological review on an important medicinal plant - *Amorphophallus paeoniifolius*. *Ayu*. 2012;33(1):27–32. doi:10.4103/0974-8520.100303.
3. Dey YN, De S, Ghosh AK, Gaidhani S, Kumari SJM. Synergistic depressant activity of *Amorphophallus paeoniifolius* in Swiss albino mice. *J Pharmacol Pharmacother*. 2011;2(2):121–3. doi:10.4103/0976-500X.81910.
4. Yuzammi, T H. Analysis of Nutrient and Anti-Nutrient Compositions of “ Suweg ” ( *Amorphophallus paeoniifolius* ) Cultivated in Java. *Elsevier*. 2019;2(1):76–83.
5. Koni T, Rusman, Hanim CZ. Nutritional composition and anti-nutritional nutrient content of Elephant Food Yam (*Amorphophallus campanulatus*). *Pak J Nutr*. 2017;16(12):935–44. doi:10.3923/pjn.2017.935.939.
6. Rahman MM, Abdullah RB. A review of oxalate poisoning in domestic animals: tolerance and performance aspects. *J Anim Physiol Anim Nutr*. 2013;97(4):605–19. doi:https://doi.org/10.1111/j.1439-0396.2012.01309.x.
7. Huang CC, W. Comparison of Taiwan paddy- and upland-cultivated taro (*Colocasia esculenta* L.) cultivars for nutritive values. *Food Chem*. 2007;102(1):250–256. doi:https://doi.org/10.1016/j.foodchem.2006.04.044.
8. Franceschi VR, H H. Calcium oxalate crystals in plants. *Bot Rev*. 1980;46:361–427. doi:http://dx.doi.org/10.1007/BF02860532.
9. Konno K, Inoue TA, M N. Synergistic Defensive Function of Raphides and Protease through the Needle Effect. *PLoS One*. 2014;9(3). doi:10.1371/journal.pone.0091341.
10. Ceretto V, Nacca N. Mucosal Injury From Calcium Oxalate Crystals Resembling Anaphylaxis and Angioedema. *J Emerg Med* . 2018;55(5):666–9. doi:10.1016/j.jemermed.2018.07.016.
11. Mrvos R, Dean BS, Philodendron KE. Philodendron/dieffenbachia ingestions: are they a problem? *J Toxicol Clin Toxicol* . 2091;29(4):485–91. doi:10.3109/15563659109025745.

#### Author biography

**Abhishek Sharma**, Quality Control Officer  <https://orcid.org/0000-0001-7325-8318>

**Gulnaz Bano**, Faculty

**Ayushi**, Student

**Cite this article:** Sharma A, Bano G, Ayushi. Type- II delayed hypersensitivity reaction by processed elephant foot yam (*Amorphophallus paeoniifolius*). *IP Int J Comprehensive Adv Pharmacol* 2022;7(1):65-67.